

# A case report of an unexpected traumatic brain injury following severe child abuse



Seyed Reza Habibzadeh<sup>1</sup>, Ehsan Bolvardi<sup>1</sup>, Esmail Rayat Dost<sup>2</sup>, Mahdi Foroughian<sup>1\*</sup>

<sup>1</sup>Department of Emergency Medicine, Faculty of Medicine, Mashhad University of Medical sciences, Mashhad, Iran

<sup>2</sup>Department of Emergency Medicine, Faculty of Medicine, Jahrom University of Medical sciences, Jahrom, Iran

**Received:** 12 August 2019  
**Accepted:** 12 September 2019  
**Published online:** 23 September 2019

**\*Corresponding author:** Mahdi Foroughian, Department of Emergency Medicine, Faculty of Medicine, Mashhad University of Medical Sciences, Mashhad, Iran. Tel: 05138525312; Email: foroughianmh@mums.ac.ir

**Competing interests:** None.  
**Funding information:** Mashhad University of Medical Sciences supported the study.

**Citation:** Habibzadeh SR, Bolvardi E, Rayat Dost E, Foroughian M. A case report of an unexpected traumatic brain injury following severe child abuse. *Journal of Emergency Practice and Trauma* 2020; 6(2): 109-111. doi: 10.34172/jept.2019.16.

## Abstract

**Introduction:** Child abuse has been defined as allowing others to cause physical, emotional, and sexual harm, and also physical and emotional pain to a child. The present study was a report on a case of physical and sexual child abuse accompanied by traumatic brain injury (TBI) referred to an emergency department.

**Case Presentation:** A 4-year-old child was rushed into an emergency department by her mother. At the time of hospital admission, the child was feeling confused and drowsy and had symptoms of hemorrhage in the right preperitoneal space as well as bleeding from the mouth. According to the pattern of the child's admission to the emergency department, contradictory descriptions by parents, clinical examinations, and TBI pattern; the probability of a case of child abuse was raised. Thus; neurosurgery, legal medicine, gynecology, and surgery consultations were requested. With regard to the brain injury and epidural hematoma, immediate measures (i.e. head lifting, taking Dilantin, blood glucose control, blood pressure control, and maintaining adequate oxygen saturation in the arterial blood) were taken to put a stop to secondary brain injury, and the patient was then transferred to the intensive care unit (ICU) for further treatments.

**Conclusion:** In the present case study, the child was seriously examined and followed up. In conclusion; 20 days later, the case was discharged from the pediatric ward with good medical conditions, and received counseling and psychiatric services for one year.

**Keywords:** Child Abuse, Injury, Trauma, Brain

## Introduction

Child abuse can have several definitions, but in general, it refers to practicing or allowing others to commit physical, emotional, and sexual harm and also cause physical and emotional pain to a child (1). This form of maltreatment can be observed in all human societies regardless of skin color, race, and sociocultural levels; characterized by a wide spectrum of psychological symptoms such as anxiety, depression, increased risks, suicidal behaviors, and physical problems induced by trauma, malnutrition as well as deficient growth (2). According to the United States Department of Health and Human Services (HHS), 2.5 million cases of child abuse were reported in 2009 including 3 700 000 children. In this respect, 80% of child abuse cases were practiced by parents and 1770 children consequently lost their lives (3). Based on the report released by the World Health Organization (WHO) in 1999, approximately 40 million 0–4-year-old children worldwide had been at the risk of abuse and neglect by their parents or caregivers, to an extent that they required the use of social and healthcare services (4). The present

study was a report on a case of physical and sexual child abuse accompanied by traumatic brain injury (TBI) referred to an emergency department.

## Case Presentation

A 4-year-old child was rushed into an emergency department by her mother. The mother's main complaint was that her child was found in their home's parking garage while her head and mouth were bleeding and they did not exactly know what had happened to the child. At the time of hospital admission, the child was feeling confused and drowsy and had symptoms of hemorrhage in the right frontoparietal space as well as bleeding from the mouth. At the onset-to-admission time, the child's symptoms were as follows; BP: 100/60; HR: 103, RR: 22; T: 37, GCS: 13/15; SPO<sub>2</sub>:98%; (RA) BS: 95.

Immediately after immobilizing the neck movement, jaw-thrust maneuver was performed to re-establish and stabilize oxygenation, oxygen was delivered, and airway suctioning was also performed. The child did not tolerate the oral airway inserted. Horse neck collar was fixed to



ensure that the cervical spine was immobilized. There were symptoms of light bleeding in the frontoparietal region that were packed. The consciousness level was evaluated by 13 out of 15 based on the GCS, the pupils had diminished and they were reactive, and there was no obvious neurological impairment.

In terms of descriptions provided by parents, each one had a different account of the cause of the trauma and there was no consistency between them. The child had no history of illnesses, allergies, or medication use. In the secondary examinations and additional clinical investigations, a 3.5-cm laceration in the right peritoneum with hematoma in the same area was observed. Following the examination of the genital organs, there were abrasions in the internal part of the left femoral region with passive genital hemorrhage and the anal region was unharmed. According to the pattern of the child's admission to the emergency department, paradoxical accounts by parents, clinical examinations as well as TBI pattern of the child; the probability of a child abuse was raised.

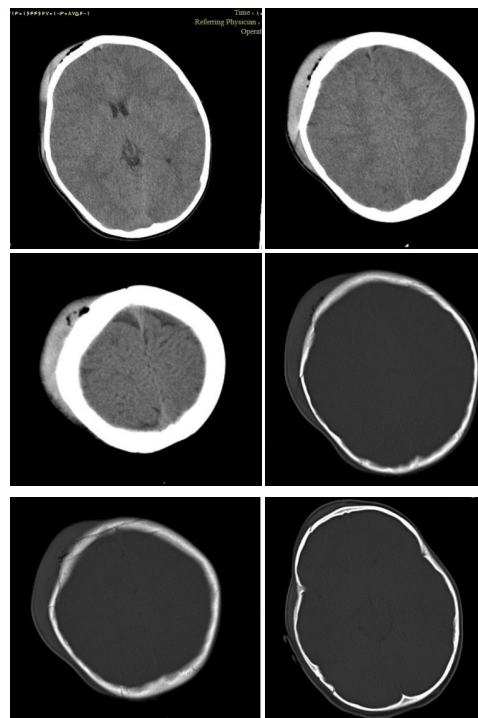
Following the brain CT scan, the symptoms of fracture of the right frontoparietal region and also the fracture of the occipital bone on the same side with a mild epidural bleeding in the right peritoneal region were seen without midline shifts (Figure 1). Other graphs and CT scans including CT-scan of the neck (Figure 2) as well as the radiography of the chest and the pelvic cavities (Figure 3) also led to no acute points. Thus; neurosurgery, legal medicine, gynecology, and surgery consultations were requested. In terms of consultations with legal medicine, evidence of a suspected case of sexual abuse was confirmed, and samples were taken from head hair, mouth, vagina, and anal region. Diagnostic tests for AIDS and hepatitis were also requested. Consulting with a gynecologist, the chance of the hymen break was verified through examination under anesthesia. The patient was also referred to a pediatric psychiatrist for counseling and psychiatric services as well as post-traumatic injury control. Finally; 20 days later, the child was discharged from the pediatric ward with good medical care. Counseling and psychiatric services also lasted for one year.

## Discussion

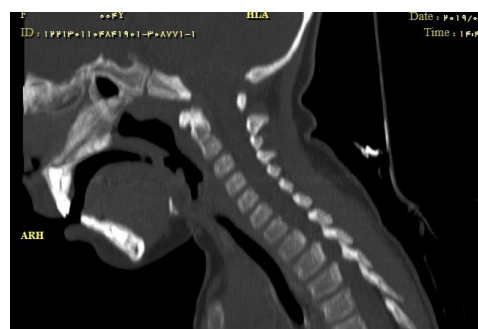Physical, emotional, and sexual abuse and neglect are four important types of child abuse (5).

In the present case study, the reported child abuse accompanied by severe physical and sexual injury was confirmed by examinations.

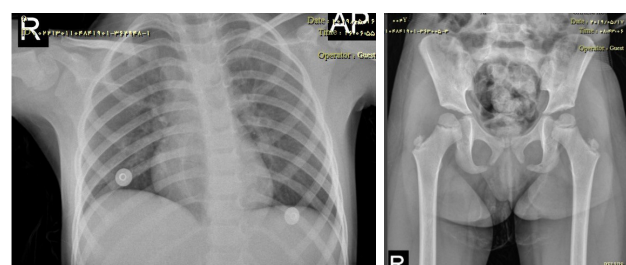
In a study in the United States on 664 cases of blunt abdominal trauma, it was reported that, with the exception of car accidents, 41% of the cases were suspected with child abuse (6). In the present case study, the examination of the abdomen did not reveal a new point. Ross et al in their study on adolescent abuse in Chinese families in Hong Kong also reported that the prevalence rate of physical abuse was 28.9%; accordingly, the prevalence rate



**Figure 1.** Brain CT scan shows the symptoms of fracture of the right preperitoneal region and also the fracture of the occipital bone on the same side with a mild epidural bleeding in the right peritoneal region were seen without midline shifts.



**Figure 2.** CT-scan of the neck shows no pathologic lesion.



**Figure 3.** Chest and the pelvic x-ray shows no abnormalities.

of mild violence was 11.2% and 16.9% in girls and boys, respectively (7). Other studies had similarly documented the prevalence rate of 3 deaths per day due to child abuse; of which, 70% were reported following injury to the head

and the neck (8,9). In the present case study, there were symptoms of light bleeding and head trauma in the right frontoparietal region.

Generally, according to statistics and figures released for child abuse worldwide and those in Iran, child abuse has not been fully reported for various reasons such as different attitudes and beliefs towards child abuse among individuals, no reporting of child abuse cases by parents due to fear of legal prosecutions, children's low age, and assuming child abuse as a routine issue as well as a sense of loyalty to parents by children (10). Therefore, it seems that there is a need to raise awareness in relation to child abuse symptoms and its accompanied risks. The medical staff is also required to precisely consider child abuse symptoms including accounts by parents and those by children as well as accurate and systematic physical examinations, since they may be neglected in a busy emergency department.

### Conclusion

In the present case study, the child was seriously examined and followed up. We must always consider child abuse in contradictory descriptions by parents, and when the clinical findings do not match to mechanism of injury. These patients need careful attention and serious follow-ups and psychiatric consultations.

### Authors' contributions

Case presentation: SRH, MF. Analysis and interpretation of data: EB, MF. Drafting of manuscript: All authors. Critical revision: MF.

### Ethical Issues

The written consent form was obtained for this report.

### References

1. Mills LG, Friend C, Conroy K, Fleck-Henderson A, Krug S, Magen RH, et al. Child protection and domestic violence: Training, practice, and policy issues. *Child Youth Serv Rev* 2000; 22(5): 315-32. doi: 10.1016/S0190-7409(00)00083-9.
2. Sadock BJ, Sadock VA. Kaplan & Sadock's Comprehensive text book of psychiatry. 7th ed. Philadelphia: Lippincott Williams & Wilkins; 2000.
3. U.S. Department of Health and Human Services, Administration for Children and Families, Administration on Children, Youth and Families, Children's Bureau. 2010. Child Maltreatment 2009. Available from: [http://www.acf.hhs.gov/programs/cb/stats\\_research/index.htm#can](http://www.acf.hhs.gov/programs/cb/stats_research/index.htm#can). Accessed May 1, 2011.
4. Christian CW, Schwarz DE. Child maltreatment and the transition to adult-based medical and mental health care. *Pediatrics* 2011; 127(1): 139-45. doi: 10.1542/peds.2010-2297.
5. Christopher J, Helga GI, Jane M. Child Abuse and Neglect. 2nd ed. London: Churchill Livingstone; 1999.
6. Trokel M, Discala C, Terrin NC, Sege RD. Patient and injury characteristics in abusive abdominal injuries. *Pediatr Emerg Care* 2006; 22(10): 700-4. doi: 10.1097/01.ped.0000238734.76413.d0.
7. Ross CA, Keyes BB, Xiao Z, Yan H, Wang Z, Zou Z, et al. Childhood physical and sexual abuse in China. *J Child Sex Abus* 2005; 14(4): 115-26. doi: 10.1300/J070v14n04\_06.
8. Shojaeizadeh D. Child abuse in the family: An analytical study. *Iran J Public Health* 2001; 30(1-2): 45-8.
9. Cairns AM, Mok JY, Welbury RR. The dental practitioner and child protection in Scotland. *Br Dent J* 2005; 199(8): 517-20. doi: 10.1038/sj.bdj.4812809.
10. Scher CD, Forde DR, McQuaid JR, Stein MB. Prevalence and demographic correlates of childhood maltreatment in an adult community sample. *Child Abuse Negl* 2004; 28(2): 167-80. doi: 10.1016/j.chiabu.2003.09.012.