



Comparison of diagnostic accuracy of bedside ultrasonography and radiography for calcaneal fractures in the emergency department

Majid Zamani¹, Maliheh Mazaheri¹, Farhad Heydari^{1*}, Babak Masoumi¹

¹Department of Emergency Medicine, Faculty of Medicine, Isfahan University of Medical Sciences, Isfahan, Iran

Received: 1 June 2020

Accepted: 14 September 2020

Published online: 24 September 2020

***Corresponding author:**

Farhad heydari; Emergency Medicine Specialist; Department of Emergency Medicine, Faculty of Medicine, Isfahan University of Medical Sciences, Isfahan, Iran Alzahra Hospital, Sofeh Ave, Keshvari Blvd., Isfahan, Iran.
Tel: +989131367643;
Email: farhad_heidari@med.mui.ac.ir

Competing interests: None.

Funding information: None.

Citation: Zamani M, Mazaheri M, Heydari F, Masoumi B. Comparison of diagnostic accuracy of bedside ultrasonography and radiography for calcaneal fractures in the emergency department. Journal of Emergency Practice and Trauma 2020; x(x): x-x. doi: 10.34172/jept.2020.36.

Abstract

Objective: Ultrasonography (US) is not the method of choice for the diagnosis of calcaneal fractures. The aim of this study was to compare the diagnostic accuracy of US with plain radiography in the diagnosis of calcaneus fractures following blunt ankle and foot trauma.

Methods: In this cross-sectional study, 214 patients (over 18 years) presenting to the emergency department (ED) with suspicion of traumatic calcaneus fracture following acute blunt trauma, were enrolled. Bedside ultrasonography was performed and interpreted by emergency physicians. After that, plain radiography was performed. Furthermore, all the patients were assessed by computed tomography (CT) scan as the gold standard.

Results: Finally, 193 patients were enrolled with a mean age of 29.4 ± 15.7 years (85.5% male). Fractures in the calcaneus were detected in 49 patients. The sensitivity and specificity of ultrasonography in the detection of calcaneal fractures were 83.6%, (confidence interval (CI), 69.7–92.2) and 100% (95% CI, 96.7–100), while the sensitivity and specificity of X-ray were 87.7% (95% CI, 74.5–94.9) and 100% (95% CI, 96.7–100). There was no false positive result for X-ray and US.

Conclusion: Our findings suggest that bedside US with an acceptable sensitivity and specificity can be used as a promising alternative for the diagnosis of calcaneal fracture in ED.

Keywords: Ultrasonography, Calcaneal fracture, Emergency department, Trauma

Introduction

Calcaneus is the largest bone of the foot and calcaneal fracture is the most common fracture of the tarsal bones (1,2). Although calcaneal fractures are uncommon, they account for approximately 1 to 3 % of the total number of fractures. Leading to long-term disability, they need rapid diagnosis and intervention (1,3). The peak incidence occurs in adolescence and young adulthood (3). Calcaneal fractures are frequently caused by major traumas, and are mostly accompanied by significant injuries. The major causes are occupational which may be due to axial loading or falling from a certain height (3,4). Typically, patients with a calcaneus fracture manifest with tenderness of the heel and hindfoot. The patient with a calcaneal fracture commonly presents with pain, swelling, and possibly deformity around the heel, ankle, and hindfoot following high energy trauma (5,6). Calcaneal fractures are diagnosed based on imaging studies, initiated with plain radiographs, including lateral and axial views. Computed

tomography (CT) scan may be needed to fully describe the fracture or to reach definitive diagnosis in some cases and should be used following high clinical suspicion of occult fracture in reported non-diagnostic radiographic findings (4,7). In recent years, the use of bedside ultrasonography (US) to evaluate patients with suspicious soft tissue or bone injuries has become increasingly more commonplace. Although plain radiography is still the initial imaging modality for the fracture identification, recently, ultrasonography has been reported to have a high sensitivity for diagnosis of fractures which might at least be partly explained by its portability, ease of use at the bedside, availability, avoidance of ionizing radiation, and low cost (6-8). The structures of the ankle and foot are superficial and can be easily evaluated by US (7,8). In this regard, accumulating lines of evidence have recently demonstrated the diagnostic efficacy of bedside US, which could be considered the choice of treatment, and also decreasing the fractures in the emergency department



(ED) (8-12).

However, to the best of our knowledge, brief studies have been performed to diagnose calcaneus fractures with US (4,6,7). In this study, we aimed to compare the efficacy of US, and plain radiography for diagnosis of suspected traumatic calcaneus fractures.

Methods

This prospective cohort study was conducted between 2013 and 2016 at the ED of Al-Zahra and Kashani hospital in Isfahan, Iran.

Patients older than 18 years and hemodynamically stable admitted with suspected traumatic calcaneus fractures following acute blunt trauma were included in this study. The patients with unstable vital signs, open wound or history of prior fracture on the injury site, definite diagnosis of fracture due to major deformity, fractures with dislocation, and those who declined to participate in the study were excluded. In addition, the patients presenting after 48 hours of trauma were not enrolled in the study.

The US was performed on all patients by one of the four independent emergency physicians (sonographers). Each sonographer received a two-hour of theoretical and a two-hour of practical instructions by another emergency medicine (EM) specialist who was an expert in musculoskeletal US. Prior to initiation of the study, all of the physicians were assessed regarding their ability to use the US for examination of calcaneal fracture. This was done by evaluating four patients under the supervision of an instructor.

EM residents performed the initial examination of patients. Afterwards, the US examinations were performed. The sonographers were blinded to the radiograph findings of the patient. After US examination, anterior-posterior,

Lateral, and Mortis view X-rays of the ankle were collected from the patients. Finally, a CT scan was performed as the gold standard. Bedside sonographic examination was performed with a Philips Affiniti 50 US Machine, with a high frequency (5-12 MHz) linear array transducer. The calcaneus was scanned on the lateral, medial, posterior and inferior of the heel.

The presence of cortical disruption, stepping, or axial deviation on the bone surface was interpreted as an ultrasonographic fracture. The radiologists who were blind to the sonographic findings evaluated the X-ray and CT images.

Data were collected and analyzed using IBM SPSS Software (V 22; Chicago, IL). Qualitative data were given as frequency and percentage, while quantitative data were given as mean and standard deviation (SD). CT scan was determined as gold standard for the diagnosis of calcaneal fracture. In addition, sensitivity, specificity, positive predictive value (PPV), negative predictive value (NPV), and likelihood ratios of US for the identification of fractures were calculated. The diagnostic agreement between the ultrasonography and plain radiography results were evaluated by analysis of the kappa score. The significance level of the tests was 0.05.

Results

In this study, 214 patients with a suspected traumatic calcaneus fracture after acute blunt traumas were randomly selected. Twenty-one patients were excluded for the following reasons: seven were excluded from the study due to previous diagnosis of calcaneal fracture prior to admission to ED, CT scan could not be obtained in four patients, three patients refused to participate in the study, four patients had open fracture, and three patients went to ED after 48 hours of trauma (Figure 1).

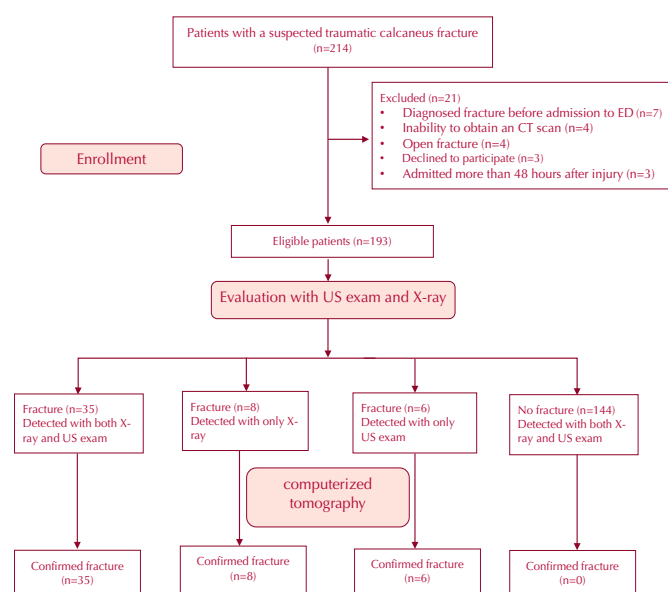


Figure 1. Flow diagram of the study

A total of 193 patients were enrolled in this study. One hundred sixty-five (85.5%) were males and 28 (14.5%) were females. The mean age of the patients was 29.4 ± 15.7 years. 107 (55.4%) of the patients, right heel injury was reported. The most common mechanisms of injury were falls from a height (144 patients, 74.6%), motorcycle crash accident (28 patients, 14.5%), and direct heel injury (16 patients, 8.3%). Baseline characteristics of the patients are shown in Table 1.

One hundred ninety-three patients underwent US exam, X-ray, and CT scan. Fracture was detected in 49 (25.4%) patients using CT scan. Forty-one patients (83.7%) were found to have fracture with US exam and 43 (87.8%) fractures were diagnosed with X-ray. Fractures were detected in 36 patients with both US exam and X-ray. Although fracture was found in the CT of 5 patients, there was no fracture in these patients based on the findings of X-ray. However, the fractures in these 6 patients were detected using US exam (six false negative results for X-ray). US exam resulted in 8 false-negative (only X-ray detected fractures). There were no cases with false positive US and X-ray findings.

(Figure 1). The Comparison results are depicted in Table 2.

In comparison with CT scan, sensitivity, specificity, NPV, PPV, and likelihood ratios of the US and plain radiography in the detection of fracture are shown in Table 3.

The area under the receiver operating characteristic (ROC) curve of US exam and X-ray in detection of calcaneus fracture was 91.8 and 93.9, respectively (Figure 2).

Discussion

Nowadays, musculoskeletal US has increasingly become the method of choice for diagnosis in many medical specialties such as sport medicine, rheumatology, anesthesia, and pain medicine. US is used for the examination of abdomen, thorax, heart, and eye (10,12-14). It is now well established that musculoskeletal US exam with an acceptable efficacy can be used for

Table 1. Baseline characteristics of the patients

Variable	
Sex, No. (%)	
Male	165 (85.5)
Female	28 (14.5)
Average age, Mean \pm SD	29.4 \pm 15.7
Side of injury, No. (%)	
Left	107 (55.4)
Right	86 (44.6)
Mechanism of injury, No. (%)	
Fall from a height	144 (74.6)
Motor crash accident	28 (14.5)
Direct blunt Injury	16 (8.3)
Others	5 (2.6)

Table 2. Comparison of US exam and X-ray results in fracture detection with CT scan

Imaging results		CT scan	
		Fracture (n = 49)	No fracture (n = 144)
US exam	Fracture (n = 41)	41	0
	No fracture (n = 152)	8	144
X-ray	Fracture (n = 43)	43	0
	No fracture (n = 150)	6	144

Table 3. Comparison of US exam and X-ray statistical results

Variable	X-ray %, (95% CI)	US exam %, (95% CI)	P value
Sensitivity	87.7 (74.5 –94.9)	83.6 (69.7 –92.2)	0.78
Specificity	100 (96.7 –100)	100 (96.7 –100)	1.00
Negative predictive value	96 (91.1 –98.3)	94.7 (89.5 –97.5)	0.86
Positive predictive value	100 (89.7 –100)	100 (89.3 –100)	1.00

the diagnosis of bone fractures and as a before-after imaging for reduction in the ED (8-12). To the best of our knowledge, this is the first study to compare US and radiography with respect to efficacy of diagnosis of calcaneal fracture. In this study, the accuracy of bedside US exam was evaluated in comparison with X-ray in the diagnosis of calcaneus fractures in the ED.

Calcaneal fractures are the result of high-energy trauma, usually due to a fall from a height or to a motor vehicle accident (15). Similarly, the most common underlying mechanisms of trauma in our study were falls from a height and motor vehicle accidents.

In our study, the sensitivity and specificity of US exam for detection of calcaneal fractures were 83.6% and 100%, respectively. On the other hand, the sensitivity and specificity for X-ray were 87.7% and 100%, respectively. There were no cases with false positive US and X-ray findings. The level of agreement between the US and plain radiography results was moderate ($k = 0.786$). Similar to our results, Haapamaki et al (16) showed sensitivity of 87% for X-Ray compared to CT scan for diagnosis of calcaneal fractures.

Although radiography is commonly used for the diagnosis of many types of bone fractures, conventional radiography is insensitive for the diagnosis of some bony injuries such as scaphoid and tibial plateau fractures. In addition, there are some challenges associated with achieving adequate calcaneal radiographs (7).

Since US has tomographic capability, it paves the way to show acute fractures—difficult to detect by using radiography, and can also show a variety of stress fractures (17). Although vigorous efforts have been made to delineate the accuracy of US and X-ray for diagnosis of fractures in lower extremities, there is still a great deal of uncertainty regarding their efficacies of calcaneal fractures diagnosis (8,14,17). In most of these studies, the

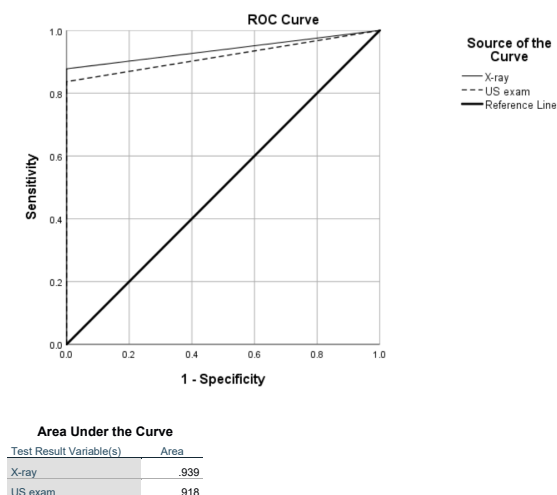


Figure 2. Area under the receiver operating characteristic (ROC) curve of ultrasound and X-ray in the detection of calcaneus fracture.

diagnostic sensitivity and specificity of US were found to be similar to plain radiography (18).

Lukac et al (4) reported a case of calcaneal fracture detected by US. This case report was the first study presented in scientific literature. Their study suggested a possible use of US for the diagnosis of fractures and also monitoring the healing process of calcaneal injuries. Augustin-Coley et al (7) showed that bedside US has the potential to be utilized as an imaging method for the diagnostic evaluation of patients with a high clinical suspicion of occult calcaneal fracture, when the plain radiography is negative.

In a case series of patients with calcaneal stress fractures, US exam detected subcutaneous edema, thickening of the periosteum, cortical bone irregularities, and local hyperemia. They suggested that US exam with clinical findings can be used to diagnose a calcaneal stress fracture (6).

Weinberg et al (19) reported that point-of-care US has an adequate diagnostic accuracy for the diagnosis of fractures in skeletally mature young adults and children with open growth plates. Their findings showed that the sensitivity and specificity of US for diagnosis of calcaneal fracture were 80% and 94%, respectively. The reported specificity in that study was similar in both young adults and children.

Atila et al (8) evaluated the accuracy of point-of-care US as a diagnostic tool for fractures in patients with ankle trauma which have indication for X-ray based on Ottawa foot and ankle rules. The US sensitivity and specificity of this study in the diagnosis of ankle and foot fractures were 87.3% and 96.4%, respectively.

They showed that the sensitivity and specificity of ultrasonography in the diagnosis of fractures could vary depending on the location of the fracture. For example, the sensitivity and specificity of ultrasonography for diagnosis of navicular fractures were lower (40% and

93.1%, respectively) than of fifth metatarsal fractures (100% and 95.6%, respectively). In our study, diagnosis of calcaneal fractures using US showed acceptable sensitivity (83.6%) and specificity (100%). However, no calcaneal fractures were detected with US in the above-mentioned study.

We detected five fractures using US that were not diagnosed by X-ray. Therefore, US exam may have superiority over X-ray in detection of occult fractures (4,6,7).

Limitations of the study

The first limitation of our study is the small sample size of patients who participated in our investigation. The other limitation of our study is the fact that no inter-reliability was defined among the sonographers.

Conclusion

In adult patients admitted with suspicion of traumatic calcaneus fractures, bedside US exam by emergency physicians showed appropriate sensitivity and specificity for the diagnosis of calcaneal fracture. It seems that evaluation of calcaneal fracture using US can be considered as a safe and feasible alternative to X-ray in ED.

Authors' contributions

MZ, FH and MM designed the research; FH, MZ and BM wrote and corrected the article; all authors collected data and approved the final version.

Ethical issues

Ethical approval was obtained from the ethical committee of Isfahan University of Medical Sciences (IR.MUI.REC.1394.3.742). Before patient enrollment, patient consent was obtained to participate in the study.

Acknowledgment

The authors appreciate the insightful cooperation of Medical Sciences and the staff of ED of Al-Zahra hospital and Kashani hospital, Isfahan, Iran.

References

1. Eiff MP, Hatch RL. Fracture Management for Primary Care. 3rd ed. Philadelphia: Elsevier Saunders; 2012.
2. Court-Brown CM, Heckman JD, McQueen MM, Ricci WM, Tornetta P, McKee MD. Rockwood and Green's Fractures in Adults. Philadelphia: Wolters Kluwer Health; 2015.
3. Sanders RW, Clare MP. Calcaneous fractures. In: Buchholz RW, Heckman JD, Court-Brown CM, Tornetta P, eds. Rockwood and Green's Fractures in Adults. 7th ed. Philadelphia: Lippincott Williams & Wilkins; 2010. p. 2064.
4. Lukac D, Milenović N, Drapsin M, Keckojević V, Sekulić S, Klasnja A. Ultrasonographic diagnostics and evaluation of calcaneal fracture: case report. Srp Arh Celok Lek 2013; 141(7-8): 532-5. doi: 10.2298/sarh1308532l.
5. Mitchell MJ, McKinley JC, Robinson CM. The epidemiology of calcaneal fractures. Foot (Edinb) 2009; 19(4): 197-200.

- doi: 10.1016/j.foot.2009.05.001.
6. Bianchi S, Luong DH. Stress fractures of the calcaneus diagnosed by sonography: report of 8 cases. *J Ultrasound Med* 2018; 37(2): 521-9. doi: 10.1002/jum.14276.
 7. Augustin-Coley BM, Pigott DC, Gibson CB, Vander Noot RM, Gullett JP. Diagnosis of a radiographically occult calcaneus fracture with bedside sonography. *J Ultrasound Med* 2016; 35(6): 1363-6. doi: 10.7863/ultra.15.08054.
 8. Atilla OD, Yesilaras M, Kilic TY, Tur FC, Reisoglu A, Sever M, et al. The accuracy of bedside ultrasonography as a diagnostic tool for fractures in the ankle and foot. *Acad Emerg Med* 2014; 21(9): 1058-61. doi: 10.1111/acem.12467.
 9. Heydari F, Samsam Shariat S, Majidinejad S, Masoumi B. The use of ultrasonography for the confirmation of pulled elbow treatment. *J Emerg Pract Trauma* 2018; 4(1): 24-8. doi: 10.15171/jept.2017.24.
 10. Hoffman DF, Adams E, Bianchi S. Ultrasonography of fractures in sports medicine. *Br J Sports Med* 2015; 49(3): 152-60. doi: 10.1136/bjsports-2014-094217.
 11. Aygün M, Yaman HF, Bayındır A. The use of ultrasonography-guided peripheral intravenous access in emergency department patients with difficult venous access. *Eurasian J Emerg Med* 2010; 9: 9-16. doi: 10.4170/jaem.2009.86580.
 12. Evrin T, Katipoglu B, Szarpak L, Yilmaz A, Ünlüer EE. A new tool in the examination of lungs in the emergency department: lung ultrasound. *Eurasian J Emerg Med* 2017; 16(3): 137-40.
 13. Heydari F, Masoumi B, Zamani M, Nasr-Esfahani M. Prospective evaluation of safe observation period after asymptomatic penetrating thoracic injury: 1 hour is enough. *Adv J Emerg Med* 2019; 3(4): e39. doi: 10.22114/ajem.v0i0.148.
 14. Golshani K, Ebrahim Zadeh M, Farajzadegan Z, Khorvash F. Diagnostic accuracy of optic nerve ultrasonography and ophthalmoscopy in prediction of elevated intracranial pressure. *Emerg (Tehran)* 2015; 3(2): 54-8.
 15. Kozaci N, Ay MO, Avci M, Beydilli I, Turhan S, Donertas E, et al. The comparison of radiography and point-of-care ultrasonography in the diagnosis and management of metatarsal fractures. *Injury* 2017; 48(2): 542-7. doi: 10.1016/j.injury.2016.12.018.
 16. Haapamaki VV, Kiuru MJ, Koskinen SK. Ankle and foot injuries: analysis of MDCT findings. *AJR Am J Roentgenol* 2004; 183(3): 615-22. doi: 10.2214/ajr.183.3.1830615.
 17. Arni D, Lambert V, Delmi M, Bianchi S. Insufficiency fracture of the calcaneum: Sonographic findings. *J Clin Ultrasound* 2009; 37(7): 424-7. doi: 10.1002/jcu.20577.
 18. Ozturk P, Aksay E, Oray NC, Bayram B, Basci O, Tokgoz D. Emergency physician accuracy using ultrasonography to diagnose lateral malleolar fracture. *Am J Emerg Med* 2018; 36(3): 362-5. doi: 10.1016/j.ajem.2017.08.020.
 19. Weinberg ER, Tunik MG, Tsung JW. Accuracy of clinician-performed point-of-care ultrasound for the diagnosis of fractures in children and young adults. *Injury* 2010; 41(8): 862-8. doi: 10.1016/j.injury.2010.04.020.