

Periorbital emphysema and pneumomediastinum following blunt orbital fracture: A case report and review of the literature



Abdolghader Pakniyat¹, Farzane Jafari², Rojin Ramezani², Mohammad Ghasemi-rad^{3*}

¹Department of Emergency Medicine, Kurdistan University of Medical Sciences, Sanandaj, Iran

²Student Research Committee, Kurdistan University of Medical Sciences, Sanandaj, Iran

³Department of interventional Radiology, Baylor college of Medicine, Houston, Texas, USA

Received: 3 March 2022
Accepted: 16 May 2022
Published online: 29 May 2022

***Corresponding author:**
Mohammad Ghasemi-rad,
Department of interventional
Radiology, Baylor college of
Medicine, Houston, Texas. Email:
mdghrad@gmail.com

Competing interests: None.

Funding information: None.

Citation: Pakniyat A, Jafari F,
Ramezani R, Ghasemi-rad M.
Periorbital emphysema and
pneumomediastinum following
blunt orbital fracture: A case report
and review of the literature. *Journal
of Emergency Practice and Trauma*
2022; 8(x): x-x. doi: 10.34172/
jept.2022.xx.

Abstract

Objective: Orbital emphysema, defined as the presence of air in orbital and periorbital tissues, is a relatively uncommon clinical condition which occurs mostly following facial trauma. It can not only resolve spontaneously without any treatment, but it can also cause life threatening complications such as pneumomediastinum (PM). PM is an uncommon complication of facial fractures and is defined as the presence of air in the mediastinal space. Developing PM following blunt trauma is commonly considered as a red flag for underlying injuries, such as trachea and esophagus rupture. Therefore, other complementary diagnostic procedures, including bronchoscopy and esophagostomy, are often necessary for patients developing this condition.

Case Presentation: A 31-year-old man with a history of facial and neck trauma was presented to the emergency room of our tertiary referral hospital with a complaint of right orbital swelling. On physical examination, vital signs were stable. There was a mild swelling of right upper eyelid, but no proptosis. An hour after admission, following sneezing and blowing his nose, the patient had further swelling of his right face with extension of swelling through the right side of his neck to the nipple. He also complained of dyspnea and acute severe progressive epigastric pain.

Conclusion: Orbital emphysema following orbital wall fracture is typically benign and self-limited, but physicians should be aware of serious complications such as PM. Therefore, monitoring the patient is crucial and should be considered in such conditions.

Keywords: Orbit, Emphysema, Pneumomediastinum, Trauma

Introduction

Orbital emphysema is a relatively uncommon clinical condition that is due to forceful entry of air into orbital or periorbital tissues. The most common causes are facial trauma with paranasal sinus fractures and Valsalva maneuvers during the early posttraumatic periods. With different mechanisms, emphysema can extend and cause other medical complications (1-4).

Pneumomediastinum (PM) is defined as the presence of air in the mediastinal space; it is an uncommon complication of facial fractures and can be life-threatening in cases of mediastinitis, pneumothorax, pneumopericardium, and PM tension (5-7).

Here, we describe a report of a 31-year-old man with orbital floor fracture who developed periorbital, neck and upper thorax emphysema, as well as PM following blunt orbital trauma.

Case Presentation

A 31-year-old man with a history of facial and neck

trauma was presented to the emergency department of our tertiary referral hospital with a complaint of right orbital swelling.

On physical examination, vital signs were stable. There was a mild swelling of the right upper eyelid, but no proptosis. Extraocular muscle motility and pupillary reflexes were normal. The patient denied any difference in visual acuity, which—based on his history—had a baseline of 9/10 and 10/10 for the right and left eye, respectively. He also denied nausea, vomiting, dizziness, nasal congestion, or bloody discharge from his nose or eye. The patient underwent spiral head CT scans, which demonstrated mildly displaced orbital floor fracture with herniation of orbital fat, air-blood level in maxillary sinus and subcutaneous emphysema in the right peri maxillary and periorbital soft tissue (Figure 1).

An hour after admission, following sneezing and blowing his nose, the patient had further swelling of his right face with extension of swelling through the right side of his neck to the nipple. He also complained of



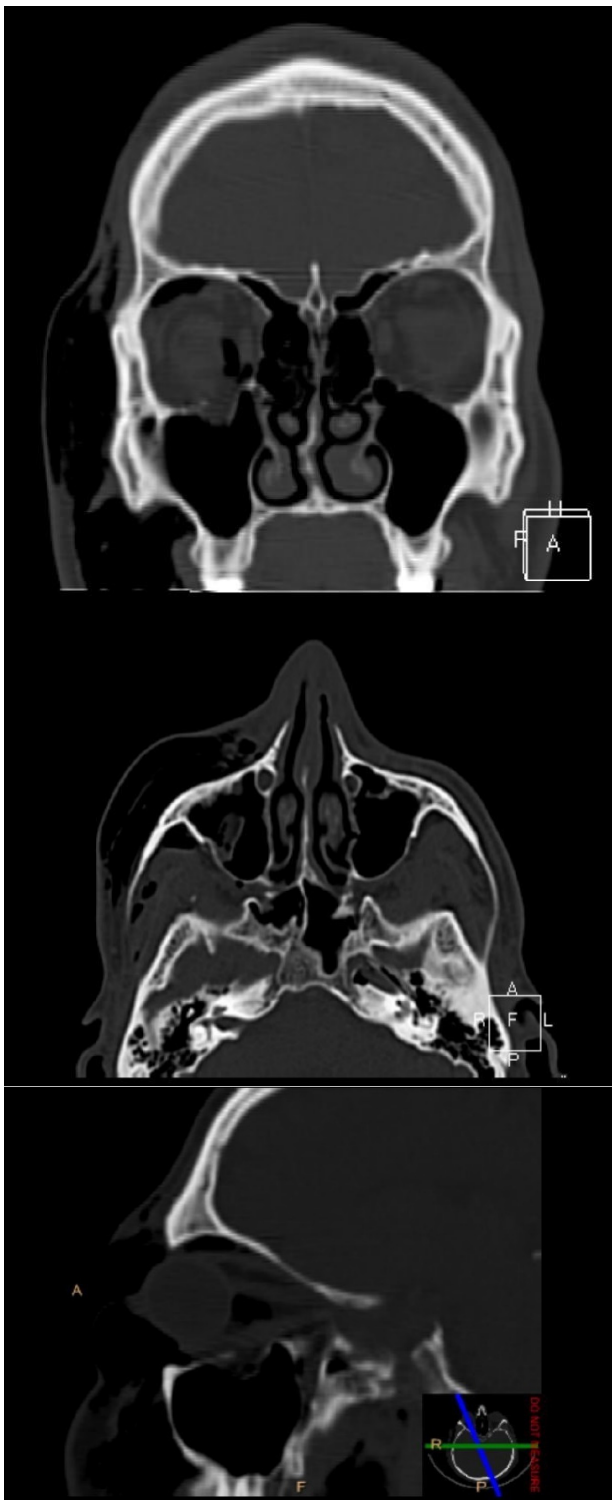

Figure 1. Coronal, Axial and sagittal bone window computed tomography of the face demonstrates mildly displaced orbital floor fracture, subcutaneous air in the right orbit as well as extensive right premaxillary and peri-orbital soft tissue.

dyspnea and acute severe progressive epigastric pain. On examination, there was tachypnea and moderate shortness of breath. The symptoms progressed rapidly, so we decided to intubate the patient given that dyspnea and emphysema were progressing and the patient was symptomatic. After the intubation (30 minutes later), ventricular tachycardia

occurred and amiodarone was injected. Once the vital signs were stabilized, echocardiography was performed that reported an ejection fraction of 60% with no pericardial effusion. The patient underwent spiral cervical and thoracic CT scans, which showed subcutaneous emphysema in the upper thorax and neck with air behind the sternum and anterior to the main arteries consistent with PM with otherwise normal findings (Figure 2).

After a few days, the hemodynamic status of the patient improved, PM was resolved in the subsequent spiral chest CT scan (Figure 3), and he was extubated. The patient subsequently underwent rigid bronchoscopy and esophagostomy due to PM; no other pathology was detected. He was discharged after a few days of observation and antibiotic therapy with the recommendation to avoid blowing his nose. Due to lack of expertise in our center, he was referred to another center for his orbital wall repair.

Discussion

Orbital emphysema is most commonly caused by the trauma and fracture of orbital bones, as in the study conducted by Birrer et al where the conventional radiographs of two thirds of patients with orbital fractures depict this condition (8).

In the present case, there was a fracture of orbital floor following trauma. Air is likely dissected from the paranasal sinuses into the orbit following pressure gradient through a one-way valve created by a fractured orbital wall and sinuses that damaged periorbital tissues, and orbital septum. In the study conducted by Ariyoshi et al., orbital emphysema occurred spontaneously after forceful nose blowing without any history of head or neck trauma. Possible reasons for this condition include aging, inflammation in the sinus associated with chronic rhinitis, and old traumas to the orbit that weaken the orbital floor and make it more susceptible to fracture with any high-pressure Valsalva maneuver (1).

Other mechanisms that develop periorbital emphysema include pulmonary barotrauma; infection; conjunctival laceration; weightlifting; bungee jumping; sinus barotrauma during airplane travel; free diving; procedures such as upper endoscopy, endoscopic retrograde cholangiopancreatography, and colonoscopy with or without perforation; Boerhaave syndrome; osteoma of paranasal sinuses; and rhegmatogenous retinal detachment repair with hyperbaric oxygen therapy (4).

One hour after admission in the present case, the patient developed PM. According to previous studies, PM can develop along the deep fascia of the neck; through perforation of the esophagus, trachea, or bronchus; from peritoneal and retroperitoneal spaces through diaphragmatic hiatuses; or straight from the lungs (9,10). The probable causes in the present study might be the extension of emphysema after nose blowing or sneezing through the deep fascia of the neck and retropharyngeal

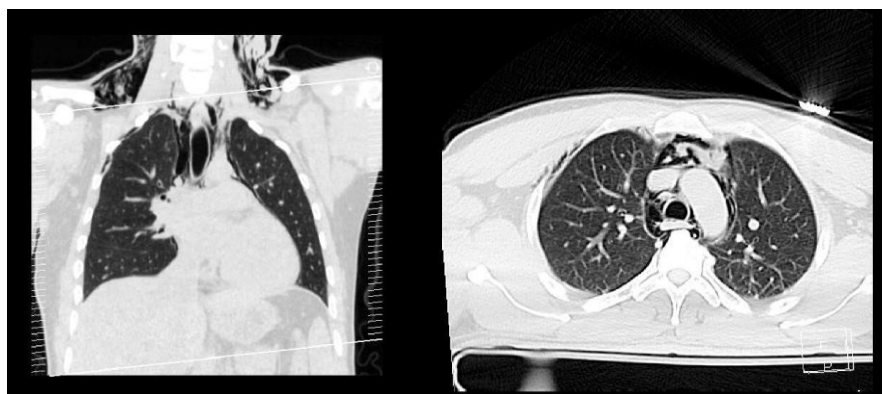


Figure 2. Coronal and axial lung window computed tomography of the chest demonstrates bilateral lower neck subcutaneous and anterior chest wall emphysema as well as pneumomediastinum.

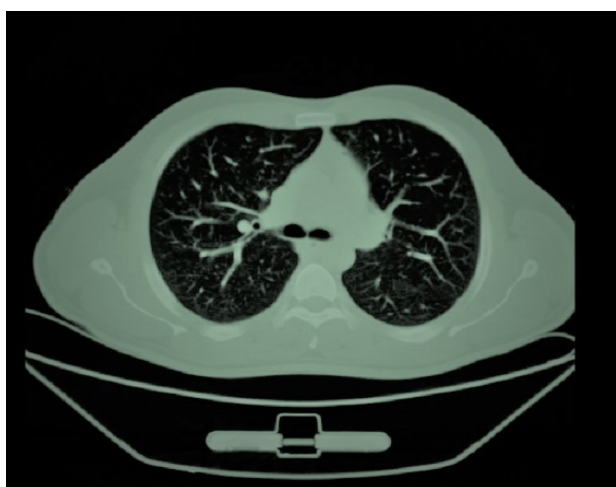

Figure 3. Axial CT of the chest, lung window at the level of upper mediastinum demonstrated resolution of pneumomediastinum.

and parapharyngeal areas to the mediastinum.

PM can be asymptomatic or cause chest pain radiating to the back, neck, and shoulders; neck pain; dyspnea; odynophagia; voice changes; or stridor and respiratory distress (7,11,12). Although the patient history and physical examination play a critical role in diagnosing periorbital emphysema and PM, imaging can also help with confirming the diagnosis and understanding the underlying mechanism. Both conventional radiography and CT scans are useful imaging modalities for detecting PM; however, the CT scan is more accurate while conventional radiography is more accessible (11,13,14).

PM following blunt trauma is commonly considered a red flag for underlying injuries such as trachea and esophagus rupture; thus, other complementary diagnostic procedures, including bronchoscopy and esophagoscopy, are often necessary for the patient to develop this condition. In the study done by Rezende-Neto et al (15), occult PM was confirmed in 6% of patients with blunt chest trauma, while in the study conducted by Neal et al (16), major aerodigestive tract injuries were seen in approximately 7% of patients with blunt trauma PM (6,11,14).

Orbital emphysema is typically a benign self-limited condition that resolves spontaneously without treatment

and is usually not associated with any complications; however, physicians should be aware of possible impediments, including vision loss due to ischemia, contusion, pressure, or central retinal artery occlusion. Antibiotic administration remains controversial, and some studies suggest using antibiotics for concomitant upper respiratory tract infection (URTI), such as acute sinusitis. Visual acuity, intraocular pressure, proptosis, and extraocular muscle motility must be examined; if any of these symptoms develop, immediate clinical procedures, such as orbital decompression, should occur. Additionally, patients should avoid Valsalva maneuvers that increase air pressure in sinuses and worsen the emphysema (1,4,13,17,18).

Managing PM depends on the underlying causes, the hemodynamic status of the patient, and the severity of symptoms. Also, it can vary from conservative (e.g. close observation, airway protection, oxygen administration, and antibiotic administration) to invasive approaches (e.g. laryngotracheal or esophageal reconstruction, tracheotomy, and thoracostomy). In patients with stable hemodynamic and no other underlying injury, using conservative approaches to avoid mediastinitis and analgesics is enough, and the PM may resolve in a few days without further medical interventions (6,7,14).

Conclusion

Orbital emphysema following orbital wall fracture is typically benign and self-limited, but physicians should be aware of serious complications such as PM. Therefore, monitoring the patient is crucial and should be considered in such conditions.

Authors' contributions

All authors contributed equally to the study design, drafting the article, reading critically and accepted the final proof.

Ethical issues

Informed consent statement was obtained from the patient for the publication of this report.

References

1. Ariyoshi Y, Naito H, Yumoto T, Iida A, Yamamoto H, Fujisaki N,

- et al. Orbital emphysema as a consequence of forceful nose-blowing: report of a case. *Case Rep Emerg Med* 2019; 2019: 4383086. doi: 10.1155/2019/4383086.
2. Mohan B, Singh KP. Bilateral subcutaneous emphysema of the orbits following nose blowing. *J Laryngol Otol* 2001; 115(4): 319-20. doi: 10.1258/0022215011907307.
 3. Moon H, Kim Y, Wi JM, Chi M. Morphological characteristics and clinical manifestations of orbital emphysema caused by isolated medial orbital wall fractures. *Eye (Lond)* 2016; 30(4): 582-7. doi: 10.1038/eye.2015.285.
 4. Zimmer-Galler IE, Bartley GB. Orbital emphysema: case reports and review of the literature. *Mayo Clin Proc* 1994; 69(2): 115-21. doi: 10.1016/s0025-6196(12)61036-2.
 5. Bars N, Atlay Y, Tülay E, Tanju G. Extensive subcutaneous emphysema and pneumomediastinum associated with blowout fracture of the medial orbital wall. *J Trauma* 2008; 64(5): 1366-9. doi: 10.1097/01.ta.0000235507.60878.3d.
 6. Cervellini G, Bellini C, Tarasconi S, Bresciani P, Lippi G. Massive pneumomediastinum following orbital fracture. *Am J Emerg Med* 2017; 35(10): 1585.e1-.e2. doi: 10.1016/j.ajem.2017.07.059.
 7. Karakisa H, Gülen M, Sönmez A, Satar S. Pneumomediastinum following orbita fracture. *Çukurova Med J* 2019; 44(2): 695-7. doi: 10.17826/cumj.493926.
 8. Birrer RB, Robinson T, Papachristos P. Orbital emphysema: how common, how significant? *Ann Emerg Med* 1994; 24(6): 1115-8. doi: 10.1016/s0196-0644(94)70241-1.
 9. Andersen C, Andersen C, 2nd, Rasmussen F. Pneumomediastinum associated with orbital fracture. Case report. *Scand J Plast Reconstr Surg Hand Surg* 1988; 22(3): 249-50. doi: 10.3109/02844318809097954.
 10. Hollinshead WH. Fascia and fascial spaces of the head and neck. In: English GM, ed. *Anatomy for Surgeons*. 2nd ed. New York: Harper & Row; 1982. p. 30-306.
 11. Abdelrahman H, Shunni A, El-Menyar A, Ajaj A, Afifi I, Zarour A, et al. Mediastinal emphysema following fracture of the orbital floor. *J Surg Case Rep* 2014; 2014(5): rju032. doi: 10.1093/jscr/rju032.
 12. Shine NP, Sader C, Coates H. Cervicofacial emphysema and pneumomediastinum following pediatric adenotonsillectomy: a rare complication. *Int J Pediatr Otorhinolaryngol* 2005; 69(11): 1579-82. doi: 10.1016/j.ijporl.2005.04.014.
 13. Tseng WS, Lee HC, Kang BH. Periorbital emphysema after a wet chamber dive. *Diving Hyperb Med* 2017; 47(3): 198-200. doi: 10.28920/dhm47.3.198-200.
 14. Sogut O, Cevik M, Boleken ME, Kaya H, Dokuzoglu MA. Pneumomediastinum and subcutaneous emphysema due to blunt neck injury: a case report and review of the literature. *J Pak Med Assoc* 2011; 61(7): 702-4.
 15. Rezende-Neto JB, Hoffmann J, Al Mahroos M, Tien H, Hsee LC, Spencer Netto F, et al. Occult pneumomediastinum in blunt chest trauma: clinical significance. *Injury* 2010; 41(1): 40-3. doi: 10.1016/j.injury.2009.06.161.
 16. Neal MD, Sippey M, Gaines BA, Hackam DJ. Presence of pneumomediastinum after blunt trauma in children: what does it really mean? *J Pediatr Surg* 2009; 44(7): 1322-7. doi: 10.1016/j.jpedsurg.2009.02.069.
 17. Lekha T, Venkatakrishnan L, Divya K, Lavanya P. Periorbital and mediastinal emphysema after upper gastrointestinal endoscopy: case report of a rare complication. *J Ophthalmic Vis Res* 2017; 12(3): 345-7. doi: 10.4103/jovr.jovr_270_15.
 18. Wood BJ, Mirvis SE, Shanmuganathan K. Tension pneumocephalus and tension orbital emphysema following blunt trauma. *Ann Emerg Med* 1996; 28(4): 446-9. doi: 10.1016/s0196-0644(96)70014-8.