

Lag screw principle to fix unstable sagittal fracture of infraorbital rim: A technical note



Smita Bhat¹, Amal Suresh¹, Apeksha Inamdar¹, Anil Kumar Desai, Gopal Krishnan¹

Department of Oral and Maxillofacial Surgery, SDM College of Dental Sciences and Hospital, A Constituent College of Shri Dharmasthala Manjunatheshwara University, Dharwad, Karnataka, India

Received: October 2, 2022

Accepted: December 15, 2022

Published online: December 26, 2022

***Corresponding author:**

Amal Suresh,

Email: dramalsuresh@gmail.com

Citation: Bhat S, Suresh A, Inamdar A, Desai AK, Krishnan G. Lag screw principle to fix unstable sagittal fracture of infraorbital rim: a technical note. *Journal of Emergency Practice and Trauma* 2023; 9(1): 52-53. doi: 10.34172/jept.2022.23.

Abstract

Objective: Fractures of orbital rims are common and restoration of these fractures back to its normal anatomic form is essential to maintain the function and aesthetics of the eyes. Low profile miniplates are the rigid fixation device of choice for such fractures. But in case of sagittal and grossly displaced fractures of orbital rims it is difficult to achieve stability by using miniplate osteosynthesis. The low profile miniplates may not be able to withstand the forces to reduce this kind if grossly displaced fractures, another stable option needs to be considered in these situations.

Case Presentation: This case report presents a simple and effective technique of reduction and fixation of an oblique fracture of infraorbital rim fracture using lag screw principle. A standard titanium screw of 2 mm diameter and 10 mm length is being used in the described technique for stable fixation of fractured segments.

Conclusion: The technique is simple, hardware's are easily available and can be practised in emergency circumstances where newer advanced technologies are not available.

Keywords: Maxillofacial surgery, Maxillofacial injuries, Fracture osteosynthesis, Orbital fractures

Introduction

Fractures of upper midface bones have both direct and indirect effects on the function and aesthetics of face, especially the eyes. This part of facial bony skeleton has impact on globe, lower eyelid and cheek positions. Due to its anatomical position and biomechanics, orbital rim fractures are common in midface injuries (1). Proper reduction and fixation of these fractures are mandatory to achieve a good functional and aesthetic outcome. Rigid internal fixation is the gold standard for fixation of the craniomaxillofacial skeleton using miniplates (2). Low profile miniplates are preferred in the fixation of fractures around the orbit. These plates cannot withstand high forces; hence a stable anatomic reduction is needed before fixation. This is not possible in case of grossly displaced fractures especially those present in conjunction with other related fractures. Effective reduction and fixation of a grossly displaced infraorbital rim sagittal fracture using lag screw fixation (LSF) principle is discussed in this article.

Case Presentation

A young male patient diagnosed with pan facial fracture underwent open reduction and internal fixation of fractured segments in our tertiary care centre. These

complicated fractures were approached through multiple facial incisions and exploring existing lacerations over the fractures. Majority of the fractures were fixed using the conventional method with titanium miniplates and screws. But left infra-orbital rim fracture was grossly displaced and required much stronger force than usual to reduce the fractured segments. **Figure 1a** shows the oblique fracture of the lateral segment of infraorbital rim associated with other multiple fractures of orbital rims. Even after manual reduction which was done by intra-oral elevation of the zygomatic bone using a long straight elevator, the segments were unstable and found to be impossible to fix it using low profile miniplates and screws. Hence, an unconventional method was followed to fix the fracture in a stable position. Once the reduction was achieved, a "gliding hole" was drilled on the proximal bone segment perpendicular to the surface, equivalent to the outer diameter of the screw, i.e. 2-mm. A coaxial "traction" hole was drilled in the distal bone fragment using a drill sleeve of 1.6 diameter which is equivalent to inner or core diameter of the screw. If the drilled hole is not coaxial, it may lead to fracture or shifting of the bone fragments or improper reduction. A 10-mm-long titanium screw of 2-mm diameter was glided through the "glide hole" passively to engage the "traction" hole



on the distal fragment. Screw was tightened to compress the proximal fragment against the distal fragment, till a stable fixation was achieved. The proximal segment was held in place by the screw head (Figure 1b). Preoperative and post-operative computed tomographic images are shown in Figure 2a and 2b. Healing was uneventful and excellent post-operative outcome was achieved which was confirmed during regular follow up examinations.

Discussion

LSF has been described as the simplest of the rigid internal fixation techniques. It requires less implant material, limited surgical exposure and has minimal post-operative complications (3). Oblique fractures are the ideal ones to be fixed by this principle. Perpendicularly placed screw will permit maximal compression and minimal risk of shift of bone segments. At least two screws are advisable to reduce the torsional forces and displacement of the segments (4). But in our case, the medial fracture of the infra orbital rim was fixed using a miniplate, which will indirectly serve

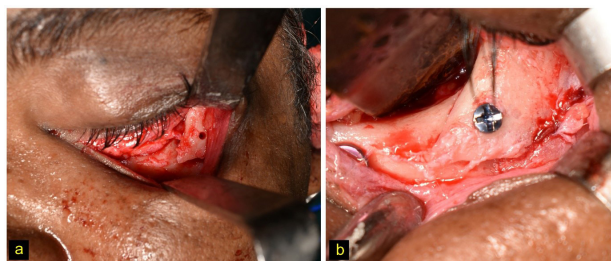


Figure 1. (a) Clinical photograph showing oblique fracture of infraorbital rim. (b) Clinical photograph showing fracture segments fixed using lag screw principle

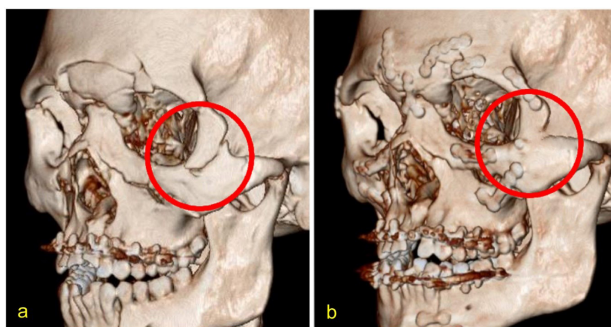


Figure 2. (a) Preoperative CT image showing fracture of infraorbital rim and other associated fractures. (b) Postoperative CT image showing fixed fracture segments using lag screw principle

the function of the second screw. A stronger and evenly distributed compression force applied by lag screw will result in more stable fixation. Hence, it is a simple and effective method for repair of sagittal fractures of midface skeleton. It can be used alone or in combination with other rigid internal fixation devices, which will help in reducing the hardware's used and is an easier technique to achieve good post-operative results (3).

Conclusion

LSF provides excellent intra-fragmentary compression and restores the pre-morbid anatomic position of fractured fragments. The application of the technique following a proper method can help the surgeon in managing complicated displaced oblique fractures of maxillofacial skeleton. Our experience shows that LSF provides excellent stability and saves intra-operative time.

Authors' Contribution

Conceptualization: Smita Bhat, Amal Suresh, Gopal Krishnan.

Data curation: Smita Bhat, Amal Suresh.

Formal Analysis: Anil Desai, Gopal Krishnan.

Methodology: Gopal Krishnan.

Resources: Gopal Krishnan, Anil Desai.

Supervision: Gopal Krishnan, Smita Bhat, Amal Suresh.

Validation: Smita Bhat, Anil Desai.

Visualization: Amal Suresh.

Writing – original draft: Amal Suresh, Apeksha Inamdar.

Writing – review & editing: Smita Bhat, Anil Desai, Gopal Krishnan.

Ethical Approval

Informed consent statement was obtained from the patient for the publication of this report.

References

1. Darwich A, Attieh A, Khalil A, Szávai S, Nazha H. Biomechanical assessment of orbital fractures using patient-specific models and clinical matching. *J Stomatol Oral Maxillofac Surg*. 2021;122(4):e51-e7. doi: 10.1016/j.jomas.2020.12.008.
2. Crespo Reinoso P, Jerez Robalino J, de Santiago MG. Biomechanics of midface trauma: a review of concepts. *J Oral Maxillofac Surg Med Pathol*. 2021;33(4):389-93. doi: 10.1016/j.ajoms.2021.01.010.
3. Ramasubbu S. Lag screws in maxillofacial trauma-a review. *J Pharm Res Int*. 2021;33(45A):105-9. doi: 10.9734/jpri/2021/v33i45A32721.
4. Kotrashetti SM, Singh AG. Prospective study of treatment outcomes with lag screw versus Herbert screw fixation in mandibular fractures. *Int J Oral Maxillofac Surg*. 2017;46(1):54-8. doi: 10.1016/j.ijom.2016.08.006.