

Purtscher's retinopathy following trauma: A case report

Seyed Ahmad Rasoulinejad^{*}



Department of Ophthalmology, Ayatollah Rouhani Hospital, Babol University of Medical Sciences, Babol, Iran

Received: April 8, 2022
Accepted: May 21, 2022
Published online: June 2, 2022

***Corresponding author:**
Seyed Ahmad Rasoulinejad,
Email: rasolisa2@gmail.com

Citation: Rasoulinejad SA.
Purtscher's retinopathy following
trauma: A case report. *Journal of
Emergency Practice and Trauma*
2023; 9(1): 58-59. doi: 10.34172/
jept.2022.10.

Abstract

Objective: Purtscher's retinopathy is the retinal damage following trauma or non-traumatic systemic disease, which may contain cotton-wool spots (CWSs), and may cause Purtscher flecken, atrophy of the optic nerve, and hemorrhage of the posterior pole of the eye.

Case Presentation: A 28-year-old male patient fell down from a height of 10 m and was admitted with swelling and ecchymosis of the peri-orbit of the right eye. The patient's vision was at the level of light perception. A mild subconjunctival hemorrhage and hyphema were seen in the right eye. In the fundus, the hemorrhage, edema, and CWS were seen in the posterior pole and around the optic disk. Macular thickness (MT) in Purtscher's retinopathic eye was 353 μm . Also, the patient had a nose and mandibular fracture and was hospitalized for several days.

Conclusion: The findings indicate a decrease in the vision due to Purtscher's retinopathy caused by trauma. There was no improvement spontaneously.

Keywords: Eye, Retina, Retinal diseases, Macular edema

Introduction

Purtscher's retinopathy is the retinal damage following trauma or non-traumatic systemic disease, which was reported in 1910 for the first time (1). Purtscher's retinopathy is a rare idiopathic disease that may lead to permanent or temporary blindness. Cotton-wool spots (CWSs), Purtscher Flecken, atrophy of the optic nerve, and hemorrhage of the posterior pole of the eye are found in Purtscher's retinopathy (2,3). Acute pancreatitis, Amniotic fluid embolism, Systemic lupus erythematosus, Thrombotic thrombocytopenic purpura, Chronic kidney failure, and Fat embolism syndrome are non-traumatic systemic diseases causing Purtscher's retinopathy (4-6).

The retinal fundoscopic examination is the primary diagnosis method (7). Also, fluorescein angiography is helpful for the evaluation of blood flow in central retinal arteriolar occlusion (8). Most cases recover after a few weeks of initial assessment without any medications. However, there are no identified medications for Purtscher's retinopathy, while there are some reports about the effect of triamcinolone on Purtscher's retinopathy (3,8).

Case Presentation

In this case report, the patient was a 28-year-old male patient who was referred three weeks after the fall from a height of 10 m. In the first examination, swelling and ecchymosis of the peri-orbit of the right eye were observed. The motion of the eye was normal in all directions, and

the relative afferent pupillary defect was negative.

The patient's vision was at the level of light perception. A mild subconjunctival hemorrhage was seen in the right eye, while the lens and cornea were normal. A mild hyphema was present in the anterior chamber of the right eye. Vitreous was clear. In the fundus, the hemorrhage, the edema, and CWS were seen in the posterior pole and around the optic disk (Figure 1). Macular thickness (MT) in Purtscher's retinopathic eye was 353 μm , while MT in a healthy eye is 226 μm . The findings indicated a decrease in the vision due to Purtscher's retinopathy caused by trauma. Meanwhile, the patient had a nose and mandibular fracture and was hospitalized for several days.

Discussion

Trauma is a primary cause of Purtscher's retinopathy (4). Evidence indicates that in cases of Purtscher's retinopathy due to the severe head injury in which the patient has lost his sight, other similar findings can be observed under conditions such as thoracic compression, acute pancreatitis, fat embolism, retrobulbar anesthesia, connective tissue disease, and childbirth. Hemorrhage and CWS are two common features in Purtscher's retinopathy (9). While there is no certain treatment for Purtscher's retinopathy, steroid therapy has been significantly reported. Systemic steroid therapy may improve vision in some patients, but there is currently little evidence to support this treatment. CWSs are the accumulation of axoplasmic material in the nerve fiber layer (10). Our case had CWSs. This retinal



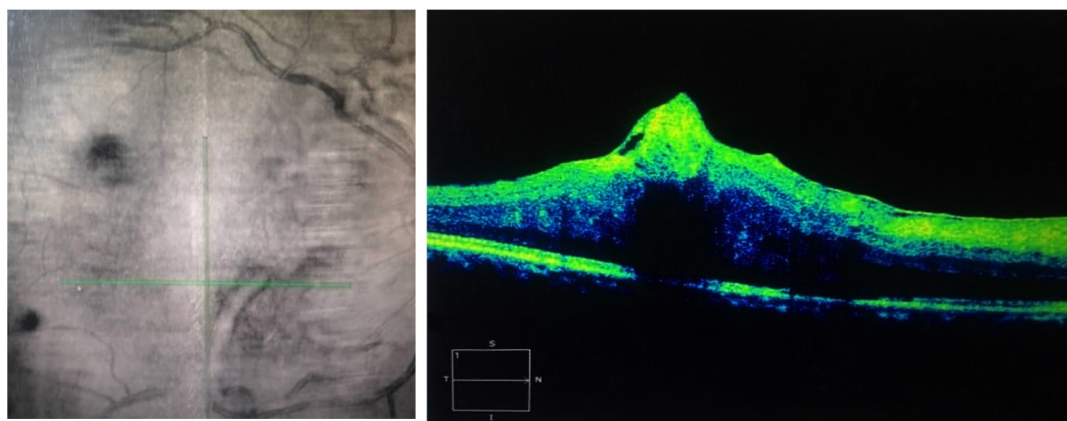


Figure 1. Optical coherence tomography of the eye.

nerve damage may lead to visual impairment. Increasing the MT was another finding in our case. MT of impaired eye increased 56.2% compared to the healthy eye. This macular edema, which is caused following trauma, is present in OCT.

After two months, there was no self-improvement in this patient without medications, while most patients are treated spontaneously. In a study by Blodi et al, three of four Purtscher's retinopathy cases were treated without any medications (11).

Conclusion

Our case was a Purtscher's retinopathy following a trauma, which did not have spontaneous improvement after two months.

Competing Interests

None.

Funding

None.

Ethical Approval

There is no ethical issue on this manuscript.

References

1. Purtscher O. Noch unbekannte befunde nach schadeltrauma. *Ber Zusammenkunft Dtsch Ophthalmol Ges.* 1910;36:294-301.
2. Ávila-Marrón E, Liscombe-Sepúlveda JP, Manfreda-Dominguez L, Rochina-Pérez P, Duch-Samper A. Purtscher's retinopathy case report: short posterior ciliary arteries contribution to radial peripapillary capillary system observed with optical coherence tomography angiography. *Int Ophthalmol.* 2019; 39(11): 2661-5. doi: [10.1007/s10792-019-01086-9](https://doi.org/10.1007/s10792-019-01086-9).
3. Alzahrani M, Rehman MA, Basodan T, Adnan I, Akhtar M. Purtscher's retinopathy in scleroderma. *GMS Ophthalmol Cases.* 2019; 9: Doc07. doi: [10.3205/oc000096](https://doi.org/10.3205/oc000096).
4. Tripathy K, Patel BC. Purtscher retinopathy. In: *StatPearls*. Treasure Island, FL: StatPearls Publishing; 2021.
5. Mishra SK, Sharma V, Kamal V, Kumar A. Purtscher's retinopathy. *QJM: An International Journal of Medicine.* 2020; 113(7): 495-6. doi: [10.1093/qjmed/hcz256](https://doi.org/10.1093/qjmed/hcz256).
6. Hussain RM, Yung CW. Purtscher's retinopathy. *Ophthalmology.* 2016; 123(8): 1666. doi: [10.1016/j.ophtha.2016.04.046](https://doi.org/10.1016/j.ophtha.2016.04.046).
7. Kasi SK, Larson J, Stewart JM. Purtscher's retinopathy. *Ophthalmology.* 2017; 124(7): 1047. doi: [10.1016/j.ophtha.2016.12.038](https://doi.org/10.1016/j.ophtha.2016.12.038).
8. Liang LL, Zhou DD, Lu CW. Purtscher-like retinopathy. *Am J Med Sci* 2017; 354(3): 330. doi: [10.1016/j.amjms.2017.02.009](https://doi.org/10.1016/j.amjms.2017.02.009).
9. Roncone DP. Purtscher's retinopathy. *Optometry.* 2002; 73(3): 166-72.
10. Mikaniki E, Rasoulinejad SA, Mikaniki M, Shirzadian AH. Purtscher's-like retinopathy. *Qom Univ Med Sci. J* 2014; 8(1): 76-9. [Persian].
11. Blodi BA, Johnson MW, Gass JD, Fine SL, Joffe LM. Purtscher's-like retinopathy after childbirth. *Ophthalmology.* 1990; 97(12): 1654-9. doi: [10.1016/s0161-6420\(90\)32365-5](https://doi.org/10.1016/s0161-6420(90)32365-5).