

Evaluation of clinical symptoms and sonographic characteristics of femoral trochlear cartilage in primary knee osteoarthritis



Bitā Abbasi¹, Masoud Pezeshki-Rad¹, Mozhdeh Amini², Mahdi Foroughian³, Maryam Sahebari⁴, Sirous Nekooei¹, Reza Akhvan^{3*}

¹Department of Radiology, Faculty of Medicine, Mashhad University of Medical Sciences, Mashhad, Iran

²Department of Radiology, Mashhad University of Medical Sciences, Mashhad, Iran

³Department of Emergency Medicine, Faculty of Medicine, Mashhad University of Medical sciences, Mashhad, Iran

⁴Department of Rheumatology, Faculty of Medicine, Mashhad University of Medical sciences, Mashhad, Iran

Received: 4 October 2019
Accepted: 1 December 2019
Published online: 8 December 2019

***Corresponding author:** Reza Akhvan, MD; Department of Emergency Medicine, Imam Reza hospital, Razi Sq., Mashhad, Iran.
Tel: (+98) 5138525004;
Fax: (+98) 5138525004;
Email: akhvanr@mums.ac.ir

Competing interests: None.

Funding information: This research was financially supported by the Chancellor for Research of Mashhad University of Medical Sciences, Mashhad, Iran

Citation: Abbasi B, Pezeshki-Rad M, Amini M, Foroughian M, Sahebari M, Nekooei S, Akhvan R. Evaluation of clinical symptoms and sonographic characteristics of femoral trochlear cartilage in primary knee osteoarthritis. *Journal of Emergency Practice and Trauma* 2020; 6(1): 18-22. doi: 10.15171/jept.2019.22.

Abstract

Objective: This study was designed to evaluate the clinical symptoms and sonographic characteristics of femoral trochlear cartilage in patients with knee joint osteoarthritis (OA).

Methods: This cross-sectional study was conducted on 94 patients with painful primary knee OA according to the American College of Rheumatology criteria with a visual analog scale pain score of 30 mm or more. Clinical features were evaluated by a rheumatologist according to the Western Ontario and McMaster Universities Osteoarthritis Index (WOMAC) criteria, and a radiologist performed ultrasonography within a week. The thickness and echogenicity grade of three cartilage regions were evaluated. Other findings such as meniscal extrusion, effusion, and Baker's cyst were recorded.

Results: The average age of patients was 60 years. The linear regression model showed a significant association of grades II and III trochlear cartilage injury with the pain index, physical activity, and WOMAC overall index. However, there was no significant association between the trochlear cartilage thickness in these three regions and the WOMAC indexes (including pain, physical activity, and the overall index). There was also no significant association between Baker's cyst and the WOMAC indexes, but a significant association was found between meniscal extrusion and the WOMAC index ($P \leq 0.001$).

Conclusion: According to our study, the echogenicity grade determined by ultrasonography of femoral trochlear cartilage affects the clinical symptoms of patients including pain. These findings indicate the role of this diagnostic device in understanding changes due to the disease, and it can help physicians focus on the pathology in order to control clinical symptoms in patients.

Keywords: Osteoarthritis, Knee, Ultrasonography, Cartilage

Introduction

Today, efficient management of the clinical symptoms of knee osteoarthritis (OA), one of the most common chronic joint diseases, has become a global health concern (1). Reduction of cartilage thickness is one of the major changes in the pathogenesis of this disease, which has been shown to be the origin of major symptoms including pain. Management of OA crucially depends on controlling pain, which is the most common symptom of this disease, causing many daily dysfunctions (2).

Imaging is an integral part of the diagnostic process, which is also applied in the follow-up and prognosis of patients (3). Use of radiography as the first and simplest diagnostic

method in these patients is very common. However, there are limitations to consider including exposure to radiation and inability to examine the cartilage and adjacent soft tissues (4-6). Although magnetic resonance imaging (MRI) is the method of choice, it is unavailable for routine clinical use because of its inaccessibility and high cost (3). On the other hand, ultrasonography is a non-radiation approach that is available and affordable. Besides examining morphological changes in the bones, it can be used to evaluate the meniscus and cartilage (7-9). Previous studies have indicated the significance of ultrasonographic findings in detecting the severity of patients' symptoms. This method is even recommended



for monitoring steroid therapy (8,9). There is also increasing evidence regarding the relationship between the findings of ultrasonography and simple radiographs (10). Yet, few studies have been conducted to show the relationship between ultrasonography and clinical findings in patients with primary knee OA (11-13). Considering the significance of controlling clinical symptoms, further investigation is needed in this area. This study aimed to evaluate the clinical symptoms and sonographic characteristics of femoral trochlear cartilage in patients with knee joint OA.

Methods

This cross-sectional study was performed on 94 patients during a 4-month period. The study population included patients aged over 40 years. According to the American College of Rheumatology (ACR) criteria (14), a rheumatologist examined the patients for painful OA of the primary knee after referral to the outpatient rheumatology clinic. After obtaining informed consent from the patients, they were recruited in this study.

The inclusion criteria were age more than 40 years, primary OA according to ACR criteria, and pain greater than 30 mm according to the visual analog scale. The exclusion criteria were secondary OA, a history of knee trauma in the previous 6 months, knee replacement or osteotomy of the targeted joint, arthroscopic surgery in the past year, analgesics use in the past 72 hours, and receiving intra-articular corticosteroid injection in the past month. The Western Ontario and McMaster Universities Osteoarthritis Index (WOMAC) (15) was used to assess the severity of clinical symptoms including pain, morning stiffness, and physical function. All the questions were read and explained to the patient by the examiner. In patients with pain in both knees, the one with more severe pain was examined; if the pain was equal in both knees, only one was examined.

In the present study, the femoral trochlear cartilage was evaluated. The examination was performed in the maximum knee flexion position (as far as possible for the patient). To examine the cartilage, a linear probe was placed in the transverse position above the patella, and the cartilage thickness was recorded at three points: in the trochlear notch, 1 cm medial to the trochlear notch, and 1 cm lateral to the trochlear notch.

To accurately measure cartilage thickness, a probe was placed in a transverse plane and perpendicular to the joint. Additionally, cartilage echogenicity was classified in these 3 grades according to the Saarakkala et al's model (7): grade 0 (normal cartilage), a monotonous anechoic band with a sharp hyperechoic anterior and posterior interfaces; grade I, degenerative changes (mild) were loss of the normal sharpness of the cartilage interfaces and/or increased echogenicity of the cartilage; grade II, degenerative changes (moderate) in addition to the aforementioned changes with clear local thinning; and

grade III, degenerative change (severe) with 100% local loss of the cartilage tissue (Figure 1).

The medial meniscal extrusion was evaluated with patients in a semi-flexed position. For this purpose, a line from the meniscal surface was drawn perpendicularly to the end-to-end line between the femur and tibia, and the line length was recorded in millimeters. If the line length was longer or equal to 3 mm, it was determined as meniscal extrusion.

In patients with primary knee OA, inflammatory changes in the joint were associated with knee pain. In order to remove them as confounding factors for pain severity, all joints were evaluated in the supine position with 30° flexion. Knee effusion exceeding 2 mm was determined as positive knee effusion. In case of synovial proliferation of more than 2 mm (a hypoechoic layer), synovitis was confirmed in the joint; either of these findings was determined as an inflammatory response in the joint.

For data analysis, linear and logistic regression tests were done to evaluate the relationship between ultrasonographic findings and clinical symptoms. SPSS software version 20 was used for this purpose. Statistically significant cutoff was considered to be at 5%.

Results

Ninety-four patients were examined in this study. The average age of patients was 60 years. The youngest patient was 41 years, whereas the oldest patient was 84 years old. Eighty-three (88.3%) women and 11 (11.7%) men were recruited in this study. Overall, 44 (44.6%) patients had joint effusion, 32 (34%) had synovitis, 4 (3.4%) had Baker's cyst, and 42 (7.44%) had meniscal extrusion.

Based on the WOMAC findings, the average pain index was 8 (range: 1-15), average physical function index was 28.6 (range: 3-57), and total WOMAC index was 37.1 (range: 4-73). In this study, the trochlear cartilage was graded in 3 regions (the midline, medial, and lateral). Furthermore, the total grade, which was the highest

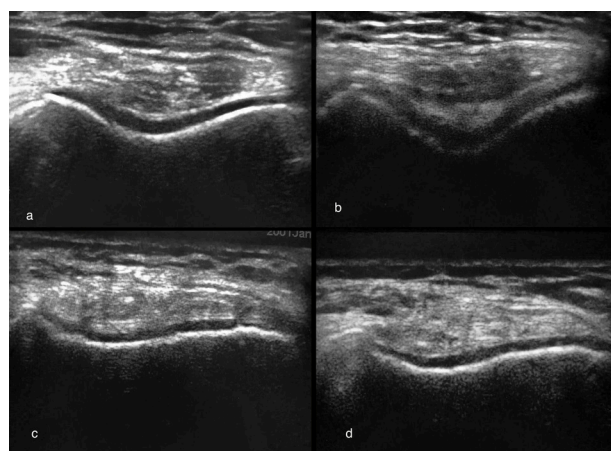


Figure 1. Ultrasound evaluation of femoral cartilage in four different patients, show various grades of femoral cartilage involvement in osteoarthritis.

cartilage grade of these regions, was measured. Overall, 7 (7.4%) patients had grade 0, 22 (23.4%) patients had grade I, 38 (40.4%) patients had grade II, and 27 (28.7%) patients had grade III cartilage damage.

The linear regression analysis showed a significant relationship between grades II and III trochlear cartilage damage in each of the regions and indices of pain, physical function, and total WOMAC (Tables 1-3). In all the analyses, the results were adjusted according to the confounding effects of inflammatory findings, such as effusion and synovitis, as well as age and sex as dependent factors. Linear regression showed no significant relationship (P values of 0.685, 0.546, 0.352, respectively) between the trochlear cartilage thickness and WOMAC indices (pain, physical function, and total index). Furthermore, there was no significant relationship (P values of 0.068, 0.053, 0.058, respectively) between the presence of Baker's cysts and the aforementioned WOMAC indices. However, there was a significant relationship between meniscal extrusion and WOMAC indices (pain, physical function, and total index) in all

three regions ($P \leq 0.001$). Moreover, the logistic regression analysis showed no significant relationship between morning stiffness, grade and thickness of trochlear cartilage, Baker's cysts, and meniscal extrusion. The risk of morning stiffness increased 6 times in grade I patients ($P = 0.09$), 11 times in grade II patients ($P = 0.28$), and 16 times in grade III patients ($P = 0.28$) (versus grade 0 for all).

Discussion

Due to technological advances, ultrasound devices with sub-millimetric resolution can evaluate even the slightest structural changes in the articular cartilage and adjacent soft tissues; these potentials can be helpful in both detecting and examining the disease course (16,17). In general, the main symptom of patients with OA is pain. Various studies have suggested the complex nature of pain and the role of various external and intraarticular factors in its occurrence (18,19).

To evaluate the grade of femoral cartilage, a semi-quantitative system described by Saarakkala et al was used (7), and there was a significant relationship between apparent cartilage changes in grades II and III and indices of pain, physical function, and total WOMAC. This grading system has been also used in previous studies, and similar results have been reported (13), confirming the role of cartilage damage and degeneration in pain and other symptoms of patients. Nonetheless, in some studies, no significant relationship was found (18, 19). Lack of a relationship for grade I may also indicate that mild cartilage damage is not the main cause of symptoms in this group of patients, and other factors are involved in the occurrence of symptoms. This issue requires further comprehensive evaluation and comparison with a control group to confirm the lack of relationship in healthy individuals.

In the present study, no significant relationship was found between the thickness of femoral cartilage in the evaluated regions and WOMAC indices. This lack of relationship

Table 1. Association between the trochlear cartilage grade and WOMAC pain index*

Location	Grade	Confidence Interval	Model Coefficient	P value
Notch	I	0.06, 3.68	1.87	0.04
	II	3.03, 6.53	4.78	0.00
	III	4.33, 8.54	6.43	0.00
Medial	I	-2.15, 0.80	-0.67	0.36
	II	1.70, 4.58	3.14	0.00
	III	2.79, 6.43	4.61	0.00
Lateral	I	-0.41, 3.07	1.33	0.13
	II	3.16, 6.44	4.80	0.00
	III	4.41, 8.31	6.36	0.00
Total	I	-1.58, 3.04	0.73	0.53
	II	1.81, 6.12	3.96	0.00
	III	3.98, 8.84	6.41	0.00

*Data are adjusted by sex, age, effusion, and synovitis.

Table 2. Association between the trochlear cartilage grade and WOMAC physical activity index*

Location	Grade	Confidence Interval	Model Coefficient	P value
Notch	I	1.09, 13.98	7.53	0.22
	II	11.71, 24.98	17.94	0.00
	III	16.40, 31.39	23.89	0.00
Medial	I	-2.93, 7.67	2.37	0.37
	II	8.70, 19.03	13.87	0.00
	III	12.92, 25.96	19.44	0.00
Lateral	I	-0.31, 12.48	6.08	0.62
	II	13.07, 25.10	19.09	0.00
	III	13.52, 27.85	20.69	0.00
Total	I	-0.75, 16.33	7.79	0.07
	II	8.62, 24.56	16.59	0.00
	III	17.11, 35.08	26.09	0.00

*Data are adjusted by sex, age, effusion, and synovitis.

Table 3. Association between the trochlear cartilage grade and total WOMAC index*

Location	Grade	Confidence Interval	Model Coefficient	P value
Notch	I	2.12, 17.67		0.13
	II	15.74, 30.77	23.25	0.00
	III	21.84, 39.94	30.89	0.00
Medial	I	-4.99, 7.92	1.46	0.65
	II	10.79, 23.38	17.09	0.00
	III	16.16, 32.06	24.11	0.00
Lateral	I	0.26, 15.65	7.96	0.43
	II	17.20, 31.67	24.43	0.00
	III	18.89, 36.21	27.60	0.00
Total	I	-1.54, 19.00	8.72	0.09
	II	11.46, 30.62	21.04	0.00
	III	22.31, 43.91	33.11	0.00

*Data are adjusted by sex, age, effusion, and synovitis.

has been also noted in some of previous studies (20). However, in some other studies, examination of this relationship was considered unnecessary due to varying degrees of cartilage thickness in different individuals (21). However, this finding can be attributed to the type of patient selection (all of whom had OA with some degree of cartilage damage) and differences in measurements. In a systematic review of 15 articles on patients with OA, 11 studies had an inaccurate measurement of cartilage borders due to cartilage changes and lack of sharpness; therefore, cartilage thickness was underestimated (22). Nonetheless, in the present study, all examinations were conducted by a single radiologist in order to reduce inaccuracy. Overall, inaccuracy of ultrasonography in measuring cartilage thickness may be a result of measurement variations and individual differences in cartilage thickness, which confirms this lack of relationship. This limitation in cartilage grading is not particularly significant or problematic, considering the semiquantitative criteria. Similarly, in a study by Kazam et al, there was a significant relationship between the cartilage grades of the patients and controls, but not with cartilage thickness (23).

Moreover, considering the significant role of inflammatory changes (joint synovitis and effusion) in the pathogenesis of OA and clinical symptoms of patients (24,25), the presence of symptoms was examined in patients, all statistical relationships were adjusted, and their possible effects on the study findings were excluded.

In this study, there was a relationship between meniscal extrusion and WOMAC indices, which was also reported in a study by Malas et al (20). However, in a study by Podlipska, there was no significant relationship with the cartilage grade after adjustments; therefore, this finding was only considered as a concomitant presentation (21). In the current study, after adjusting for the cartilage grade, there was a significant relationship with all WOMAC indices, indicating their independent role in the development of clinical symptoms.

In this study, the absence of a control group for evaluating the relationships in healthy individuals to determine whether these relationships were related to the disease is one of the limitations. Moreover, there was no reference or evidence (such as MRI or arthroscopy findings) to confirm the ultrasonographic findings in our study. Furthermore, various factors can contribute to the clinical symptoms of patients including osteophytes, erosion, alignment, and even psychological issues (3, 21), which were not considered in the present study. In fact, lack of cartilage grade changes in 7.4% of patients, despite having symptoms, can indicate the role of other factors in the clinical symptoms of patients.

Conclusion

Similar to previous research, our study confirmed the accuracy and capacity of ultrasonography in detecting changes in the course of OA; therefore, ultrasonography

is an efficient tool in the diagnosis of musculoskeletal disorders. Nonetheless, further studies are suggested to examine the effects of cartilage-boosting drugs on reducing patients' clinical symptoms. The presence of this relationship can help rheumatologists control severe pain in patients with higher cartilage grades; however, further confirmatory studies are necessary.

Authors' contributions

All authors read and accepted the final draft of manuscript. Data collection performed by MPR, MA, BA, SN. Data analysis performed by BA, MPR, MA, SN, RA. Critical revision of manuscript done by BA, RA, MS, MF.

Ethical Issues

This cross-sectional study was approved by the Chancellor for Research of Mashhad University of Medical Sciences (Ethical code: IR.MUMS.fm.REC.1395.240).

References

1. Bijlsma JW, Berenbaum F, Lafeber FP. Osteoarthritis: an update with relevance for clinical practice. *Lancet* 2011; 377(9783): 2115-26. doi: 10.1016/s0140-6736(11)60243-2.
2. Goldring MB, Goldring SR. Articular cartilage and subchondral bone in the pathogenesis of osteoarthritis. *Ann N Y Acad Sci* 2010; 1192: 230-7. doi: 10.1111/j.1749-6632.2009.05240.x.
3. Roemer FW, Eckstein F, Hayashi D, Guermazi A. The role of imaging in osteoarthritis. *Best Pract Res Clin Rheumatol* 2014; 28(1): 31-60. doi: 10.1016/j.berh.2014.02.002.
4. Hayashi D, Roemer FW, Guermazi A. Imaging for osteoarthritis. *Ann Phys Rehabil Med* 2016; 59(3): 161-9. doi: 10.1016/j.rehab.2015.12.003.
5. Amin S, LaValley MP, Guermazi A, Grigoryan M, Hunter DJ, Clancy M, et al. The relationship between cartilage loss on magnetic resonance imaging and radiographic progression in men and women with knee osteoarthritis. *Arthritis Rheum* 2005; 52(10): 3152-9. doi: 10.1002/art.21296.
6. Gale DR, Chaisson CE, Totterman SM, Schwartz RK, Gale ME, Felson D. Meniscal subluxation: association with osteoarthritis and joint space narrowing. *Osteoarthritis Cartilage* 1999; 7(6): 526-32. doi: 10.1053/j.joca.1999.0256.
7. Saarakkala S, Waris P, Waris V, Tarkkiainen I, Karvanen E, Aarnio J, et al. Diagnostic performance of knee ultrasonography for detecting degenerative changes of articular cartilage. *Osteoarthritis Cartilage* 2012; 20(5): 376-81. doi: 10.1016/j.joca.2012.01.016.
8. Wu PT, Shao CJ, Wu KC, Wu TT, Chern TC, Kuo LC, et al. Pain in patients with equal radiographic grades of osteoarthritis in both knees: the value of gray scale ultrasound. *Osteoarthritis Cartilage* 2012; 20(12): 1507-13. doi: 10.1016/j.joca.2012.08.021.
9. Podsiadlo P, Cicuttini FM, Wolski M, Stachowiak GW, Wluka AE. Trabecular bone texture detected by plain radiography is associated with an increased risk of knee replacement in patients with osteoarthritis: a 6 year prospective follow up study. *Osteoarthritis Cartilage* 2014; 22(1): 71-5. doi: 10.1016/j.joca.2013.10.017.

10. Yoon CH, Kim HS, Ju JH, Jee WH, Park SH, Kim HY. Validity of the sonographic longitudinal sagittal image for assessment of the cartilage thickness in the knee osteoarthritis. *Clin Rheumatol* 2008; 27(12): 1507-16. doi: 10.1007/s10067-008-0956-3.
11. Abbasi B, Pezeshki-Rad M, Akhavan R, Sahebari M. Association between clinical and sonographic synovitis in patients with painful knee osteoarthritis. *Int J Rheum Dis* 2017; 20(5): 561-6. doi: 10.1111/1756-185x.12834.
12. de Miguel Mendieta E, Cobo Ibáñez T, Usón Jaeger J, Bonilla Hernán G, Martín Mola E. Clinical and ultrasonographic findings related to knee pain in osteoarthritis. *Osteoarthritis Cartilage* 2006; 14(6): 540-4. doi: 10.1016/j.joca.2005.12.012.
13. Chen YJ, Chen CH, Wang CL, Huang MH, Chen TW, Lee CL. Association between the severity of femoral condylar cartilage erosion related to knee osteoarthritis by ultrasonographic evaluation and the clinical symptoms and functions. *Arch Phys Med Rehabil* 2015; 96(5): 837-44. doi: 10.1016/j.apmr.2015.01.004.
14. Johns Hopkins Arthritis Center. ACR Diagnostic Guidelines. [cited 2019 Dec 25] Available from: https://www.hopkinsarthritis.org/physician-corner/education/arthritis-education-diagnostic-guidelines/#class_knee.
15. WOMAC Osteoarthritis Index [internet]. [cited 2019 Dec 25]. Available from: <http://www.womac.com/womac/index.htm#meast>.
16. Havelaar KJ. Proceedings: Specificity of a bacteriophage T2-induced DNA methylase. *Hoppe Seylers Z Physiol Chem* 1974; 355(10): 1202-3.
17. Bevers K, Bijlsma JW, Vriesekolk JE, van den Ende CH, den Broeder AA. Ultrasonographic features in symptomatic osteoarthritis of the knee and relation with pain. *Rheumatology (Oxford)* 2014; 53(9): 1625-9. doi: 10.1093/rheumatology/keu030.
18. Hunter DJ, Guermazi A, Roemer F, Zhang Y, Neogi T. Structural correlates of pain in joints with osteoarthritis. *Osteoarthritis Cartilage* 2013; 21(9): 1170-8. doi: 10.1016/j.joca.2013.05.017.
19. Neogi T. The epidemiology and impact of pain in osteoarthritis. *Osteoarthritis Cartilage* 2013; 21(9): 1145-53. doi: 10.1016/j.joca.2013.03.018.
20. Malas FÜ, Kara M, Kaymak B, Akıncı A, Özçakar L. Ultrasonographic evaluation in symptomatic knee osteoarthritis: clinical and radiological correlation. *Int J Rheum Dis* 2014; 17(5): 536-40. doi: 10.1111/1756-185x.12190.
21. Podlipská J, Koski JM, Kaukinen P, Haapea M, Tervonen O, Arokoski JP, et al. Structure-symptom relationship with wide-area ultrasound scanning of knee osteoarthritis. *Sci Rep* 2017; 7: 44470. doi: 10.1038/srep44470.
22. Torp-Pedersen S, Bartels EM, Wilhjelmsen J, Bliddal H. Articular cartilage thickness measured with US is not as easy as it appears: a systematic review of measurement techniques and image interpretation. *Ultraschall Med* 2011; 32(1): 54-61. doi: 10.1055/s-0029-1245386.
23. Kazam JK, Nazarian LN, Miller TT, Sofka CM, Parker L, Adler RS. Sonographic evaluation of femoral trochlear cartilage in patients with knee pain. *J Ultrasound Med* 2011; 30(6): 797-802. doi: 10.7863/jum.2011.30.6.797.
24. D'Agostino MA, Conaghan P, Le Bars M, Baron G, Grassi W, Martin-Mola E, et al. EULAR report on the use of ultrasonography in painful knee osteoarthritis. Part 1: prevalence of inflammation in osteoarthritis. *Ann Rheum Dis* 2005; 64(12): 1703-9. doi: 10.1136/ard.2005.037994.
25. Abbasi B, Akhavan R, Seilanian Toosi F, Nekooei S. A man with disabling low back pain: echinococcus of the sacrum. *Int J Infect Dis* 2016; 49: 68-70. doi: 10.1016/j.ijid.2016.06.001.