

Hyperkalemia-induced complete heart block

Alireza Baratloo¹, Pauline Haroutunian^{2*}, Alaleh Rouhipour³, Saeed Safari¹, Farhad Rahmati¹

¹Department of Emergency Medicine, Shohadaye Tajrish Hospital, Shahid Beheshti University of Medical Sciences, Tehran, Iran

²Department of Medicine, Shahid Beheshti University of Medical Sciences, Tehran, Iran

³Department of Pediatrics, Valiasr Hospital, Ghazvin University of Medical Sciences, Abyek, Iran

Received: 5 March 2014

Accepted: 17 July 2014

Published online: 21 December 2014

***Corresponding author:** Pauline

Haroutunian, Department of Emergency Medicine, Shohadaye Tajrish hospital, Shahid Beheshti University of Medical Sciences, Tehran, Iran. Tel: +989122884364; Fax: +982122721155; E-mail: Pauline_e25@hotmail.com

Competing interests: The authors declare that no competing interests exist.

Funding information: There is none to be declared.

Citation: Baratloo A, Haroutunian P, Rouhipour A, Safari S, Rahmati F. Hyperkalemia-induced complete heart block. Journal of Emergency Practice and Trauma 2015; 1(1): 35-38.

Abstract

Background: Potassium, as an extracellular ion, plays an important role in the electrophysiologic function of the myocardium and any change in extracellular concentration of this ion might have a marked impression upon myocyte electrophysiologic gain. High serum potassium levels are thought to impair pulse conduction in Purkinje fibers and ventricles more than that in the Atrioventricular (AV) node. Therefore, although complete AV block can occur, it is a rare initial presentation.

Case Report: We describe a 62-year-old man with a history of diabetes mellitus, ischemic heart disease and previous Coronary Artery Bypass Graft (CABG), who came to our emergency department due to generalized weakness starting 2 days before admission. The patient also had decreased force in lower limbs, exacerbating from the morning, and was finally diagnosed as a hyperkalemia-induced Complete Heart Block (CHB). It should also be noted that the patient responded dramatically to the administration of 10 mL of 10% calcium gluconate along with external pacing until potassium level correction became effective.

Conclusion: In spite of the fact that Hyperkalemia can be associated with frequent Electrocardiogram (ECG) abnormality, advanced heart blocks (second- and third-degree AV blocks) are usually found only in patients with pre-existing heart failure, conduction abnormalities, or other cardiac diseases. Institution of effective treatment rapidly and forgiveness of traditional non-effective, time consumptive and sometimes risking full-adjustment modalities, such as sodium bicarbonate infusion or exchange resins that prevent their use in the emergent phase, can help minimize patient morbidity and mortality.

Keywords: Hyperkalemia, Complete heart block, External pacing

Background

Potassium is an extracellular ion with an important role in the electrophysiologic regulation of myocardial function. Different concentrations of high intracellular and low extracellular potassium ions, the opposite of which is true for sodium ion, are maintained by sodium potassium adenosine triphosphatase (Na-K ATPase) pumps, giving rise to a resting membrane potential of -90 mV across the myocytes membrane. As a result, any change in extracellular potassium concentration may have a significant effect on myocyte electrophysiologic gain (1).

Hyperkalemia is a prevalent and potentially fatal electrolyte disturbance. The incidence of Hyperkalemia in the general population is unknown, but it occurs in 1–10% of hospitalized patients, with a mortality rate of 1 in 1,000 patients (2).

Although the electrocardiogram may show changes suggestive of Hyperkalemia, diagnosis is usually based on

laboratory studies. Hyperkalemia can be associated with frequent electrocardiographic abnormalities. In general, Hyperkalemia results in a gradual decrease in the excitability and conduction velocity of specialized pacemaker cells and conducting tissues throughout the heart. Typical Electrocardiogram (ECG) findings in Hyperkalemia progress from tall, "peaked" T waves and a shortened QT interval to a lengthening of PR interval and loss of P waves, and then to widening of the QRS complex, culminating in a "sine wave" morphology and death if not treated (3-6). High serum potassium levels are thought to impair the conduction in Purkinje fibers and ventricles more than that in the AV node; although complete Atrioventricular (AV) block can occur, it is one of the rarest initial presentations (7).

Case Report

The patient was a 62-year-old man who was admitted into



our emergency department due to generalized weakness, nausea and frequent vomiting from 2 days before and also decreased force in lower limbs, which had deteriorated since that morning. He was alert when admitted into the emergency department but complained of pain in left hemithorax accompanied by cold sweating which had begun 3 hours previously.

He had a positive history of diabetes mellitus for the previous 20 years, ischemic heart disease and previous Coronary Artery Bypass Graft (CABG), for the former 3 years as well. He also had a history of hospital admission due to raised Blood Urea Nitrogen (BUN) and creatinine, and was treated with one time hemodialysis in the previous year. Nitrocontin, Spironolactone, Aspirin (ASA), Furosemide, Enalapril, Carvedilol and Insulin were the drugs that he used regularly.

When he was admitted into the emergency department he had a respiratory rate of 22/min, a pulse rate of 28/min, a blood pressure of 75/55 mmHg, and his blood sugar was 170 mg/dL.

His ECG revealed CHB (Figure 1a) which was immediately treated with transcutaneous pacing and atropine (Figure 1b).

Laboratory examination revealed the following: K= 8 mg/dL, BUN= 110 mg/dL, creatinine= 5.13 mg/dL and Mg= 2.6 mg/dL. Arterial Blood Gas (ABG) test results were: pH= 7.23, PCO₂= 29.5, HCO₃= 12.2 and BE= -13.8.

Because of obvious Hyperkalemia and its apparent cardiac conductive effects, 10 mL of 10% calcium gluconate was administered immediately, which resulted in dramatic heart block elimination (Figure 1c).

Infusion of 50% glucose plus insulin was instituted; kayexalate was also administered via a nasogastric tube. He was prepared for hemodialysis simultaneously.

He was admitted into the CCU for the rest of the treatment after hemodialysis and was discharged without any problems 3 days later (Figure 2).

Discussion

Although the ECG is not considered as a reliable indicator

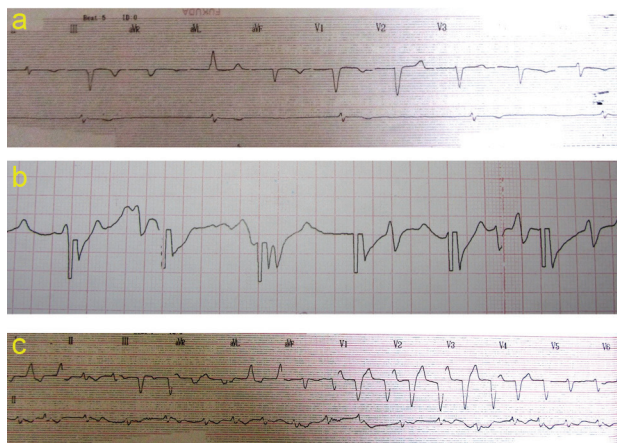


Figure 1. a) First ECG. b) ECG after transcutaneous pacing. c) ECG after calcium gluconate administration

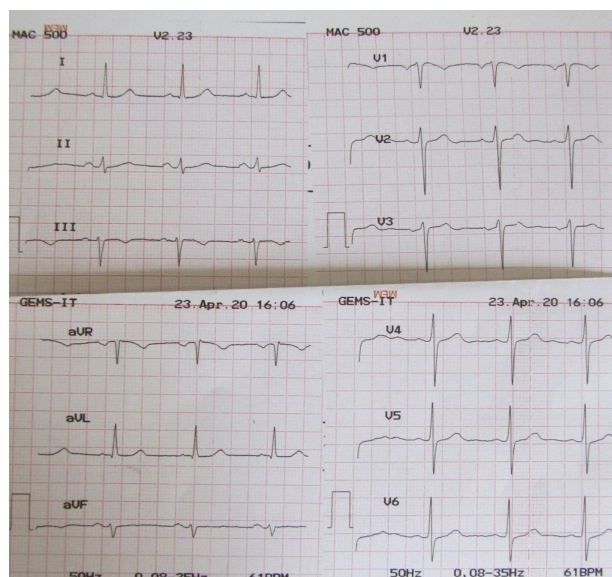


Figure 2. ECG after hemodialysis.

of mild to moderate Hyperkalemia, profound elevations of serum potassium concentrations generally produce classic ECG manifestations, but some reports are available of severe hyperkalemia (greater than 9.0 mEq/L) with ECGs not revealing the expected manifestations of Hyperkalemia. Thus, even with profound serum potassium elevations, the ECG cannot reliably be used to exclude Hyperkalemia or to monitor therapy designed to lower the serum potassium concentration (7,8).

CHB occurs when all the electrical transmission is lost from the supraventricular tissues to ventricles. The lower level of block, the slower and the less reliable will be the ventricular escape rhythm. Third-degree AV block can be congenital or acquired. In general, congenital third-degree AV block is associated with a narrow complex escape rhythm and fewer symptoms. Ischemic heart disease, drugs, and Hyperkalemia are some common causes of acquired CHB. On the other hand, cardiomyopathies, myocarditis, structural heart disease, hypothermia, and severe hypothyroidism are much less common causes. Acquired third-degree AV block often has a wide complex escape rhythm, with symptoms of hypoperfusion at rest or with minimal exertion. CHB may be subacute/chronic and relatively well tolerated providing that the block occurs at a relatively high level, (A-V nodal to His bundle region). Alternatively the patient may be very unwell, usually in acute onset in association with myocardial ischemia or a low level block (8,9).

In spite of the fact that Hyperkalemia can be associated with frequent ECG abnormality, advanced heart blocks (second- and third-degree AV blocks) are usually seen only in patients with pre-existing heart failure, conduction abnormalities, or other cardiac diseases (3,4). Underlying coronary artery disease or diffuse cardiac diseases were thought to have already damaged the conduction path through the AV node and His-Purkinje system, and an

elevated potassium level only further worsened this pre-existing conduction abnormality (4,5).

Treatment of patients with third-degree AV block depends on the symptoms. A temporary pacemaker will be necessary in all the patients with CHB, who do not respond to medical intervention. Patients with clinical evidence of hypoperfusion are best treated with transcutaneous pacing and close clinical assessment. While atropine is often used in the field, it rarely helps or harms, usually simply alters the conduction ratios without changing the escape rhythm. The patient should be admitted into an appropriate monitoring unit if acquired or symptomatic third-degree AV block is diagnosed. Initially, external pacing (via skin pacing pads) may be successful in urgent cases in the ED. This is useful as a temporary measure until the patient stabilizes and treatment of the underlying cause becomes effective or a more definitive pacemaker is placed (7,9).

The goal of life-threatening Hyperkalemia treatment is to block its effects on myocyte membrane, cardiac conduction and initiation of further steps to decrease extracellular potassium levels (6). Most of the current recommendations emphasize that Hyperkalemia should be treated with the appearance of electrocardiographic changes or when serum potassium levels are higher than 6.5 mEq/L, regardless of the electrocardiogram (10).

The treatment for Hyperkalemia can be thought of in 3 distinct steps. The first step is to antagonize the effects of Hyperkalemia at cellular level (membrane stabilization). Calcium (intravenous calcium chloride or gluconate) can effectively block the effect of extracellular potassium elevation on cardiac myocytes within minutes by restoring a more appropriate electrical gradient across the cellular membrane. The second step is to decrease serum potassium levels by promoting the influx of potassium into cells throughout the body. Combination of Glucose and Insulin, Beta-2 adrenergic agonists and Sodium bicarbonate drives potassium intracellularly and lowers the extracellular serum potassium level. The third step is to remove potassium from the body. Excessive body potassium can be removed with sodium polystyrene sulfonate (kayexalate), whereas hemodialysis represents the definitive method to reduce serum potassium levels (5,6,10).

Sodium bicarbonate infusion is used with the aim of shifting extracellular potassium to intracellular space by raising blood pH (11,12). In a study by Blumberg *et al.*, no significant change in potassium levels occurred until 4 hours after sodium bicarbonate administration and only a decrease of 0.35 mEq/L was seen after 6 hours (13). Due to the lack of a quick or sustained decrease in potassium levels, routine bicarbonate therapy for the treatment of Hyperkalemia is controversial and it is better to reserve its use for situations in which severe acidemia is present or there is another indication for its administration (10). Most studies have shown that exchange resins decrease serum potassium levels by about 1 mEq/L over a 24-hour period. Therefore, their long time requirement precludes

their use in emergency and fatal situations. In addition, because of high probability of significant constipation induced by exchange resins, combination with a laxative, such as sorbitol, is ordinarily considered. Although generally safe, the combination of a resin with sorbitol has been reported to cause intestinal necrosis; therefore, it should be used cautiously and only when necessary (9,14,15).

Conclusion

Hyperkalemia is a commonly encountered electrolyte abnormality that can lead to life-threatening derangements in cardiac conduction. The emergency medicine physician and specialist should be aware of the range of dysrhythmia attributed to Hyperkalemia, including CHB which is rare but can occur, especially in patients with pre-existing heart failure, conduction abnormalities, or other cardiac diseases. Institution of effective treatment rapidly and forgiveness of traditional non-effective, time consumptive and sometimes risking full adjustment modalities, such as sodium bicarbonate infusion or exchange resins that exclude their use in the emergent phase, can help minimize patient morbidity and mortality.

Acknowledgments

We would like to thank all emergency department personnel of Shohadaye Tajrish Hospital whose help was crucial in appropriate diagnosis and management of this patient.

Ethical issues

This study is compatible with Helsinki Rules for ethics in research studies that was approved by the ethic committee of Shahid Beheshti University of Medical Sciences.

Authors' contributions

AB and FR managed the patient in ED and collected the data. AR wrote the first draft and collected more data with internet research. AB and SS commented on the final manuscript and PH provided critical revisions.

Summary points

- ▶ **Why is this topic important?** Hyperkalemia is one of the curable emergency conditions that can be presented with lots of manifestation.
- ▶ **What does this study attempt to show?** It tries to discuss one of the rare cases of hyperkalemia that is presented with complete heart block as a first manifestation.
- ▶ **What are the key findings?** We explained risk factors, manifestations, and also treatment options of hyperkalemia-induced complete heart block in a summary via a case presentation as an educational case study.
- ▶ **How is patient care impacted?** This paper reported a correct patient care in an emergency department as a guide for all emergency physicians and staff.

References

1. Dananberg J. Electrolyte abnormalities affecting the heart. In: Schwartz GR, editor. Principles and practice of emergency medicine. 4th ed. Baltimore: Williams & Wilkins; 1999. p. 425-7.
2. Sood MM, Sood AR, Richardson R. Emergency management and commonly encountered outpatient scenarios in patients with hyperkalemia. *Mayo Clin Proc* 2007; 82(12): 1553-61.
3. Alfonzo AV, Isles C, Geddes C, Deighan C. Potassium disorders—clinical spectrum and emergency management. *Resuscitation* 2006; 70(1): 10-25.
4. Slovis C, Jenkins R. ABC of clinical electrocardiography: Conditions not primarily affecting the heart. *BMJ* 2002; 324 (7349): 1320-3.
5. Webster A, Brady W, Morris F. Recognising signs of danger: ECG changes resulting from an abnormal serum potassium concentration. *Emerg Med J* 2002; 19 (1): 74-7.
6. Diercks DB, Shumaik GM, Harrigan RA, Brady WJ, Chan TC. Electrocardiographic manifestations: electrolyte abnormalities. *J Emerg Med* 2004; 27 (2): 153-60.
7. Kim NH, Oh SK, Jeong JW. Hyperkalaemia induced complete atrioventricular block with a narrow QRS complex. *Heart* 2005; 91 (1): e5.
8. Smith SC Jr, Benjamin EJ, Bonow RO, Braun LT, Creager MA, Franklin BA, *et al.* AHA/ACCF secondary prevention and risk reduction therapy for patients with coronary and other atherosclerotic vascular disease: 2011 update: a guideline from the American Heart Association and American College of Cardiology Foundation endorsed by the World Heart Federation and the Preventive Cardiovascular Nurses Association. *J Am Coll Cardiol* 2011; 58(23): 2432-46.
9. Yealy DM, Delbridge TR. Dysrhythmias. In: Marx J, Hockberger R, Walls R, editors. Rosen's Emergency Medicine Concepts and Clinical Practice. 7th ed. Philadelphia: Mosby; 2007. p. 1000-2.
10. Parham WA, Mehdirdad AA, Biermann KM, Fredman CS. Hyperkalemia revisited. *Tex Heart Inst J* 2006; 33(1): 40-7.
11. Kamel KS, Halperin ML, Faber MD, Steigerwalt SP, Heilig CW, Narins RG. Disorders of potassium balance. In: Brenner BM, Rector FC, editors. Brenner & Rector's the kidney. 5th ed. Philadelphia: WB Saunders; 1996. p. 999-1037.
12. Kaplan JL, Braitman LE, Dalsey WC, Montgomery M, Mangione A. Alkalinization is ineffective for severe hyperkalemia in nonnephrectomized dogs. Hyperkalemia Research Group. *Acad Emerg Med* 1997; 4(2): 93-9.
13. Blumberg A, Weidmann P, Ferrari P. Effect of prolonged bicarbonate administration on plasma potassium in terminal renal failure. *Kidney Int* 1992; 41(2): 369-74.
14. Gerstman BB, Kirkman R, Platt R. Intestinal necrosis associated with postoperative orally administered sodium polystyrene sulfonate in sorbitol. *Am J Kidney Dis* 1992; 20 (2): 159-61.
15. Dardik A, Moesinger RC, Efron G, Barbul A, Harrison MG. Acute abdomen with colonic necrosis induced by Kayexalate-sorbitol. *South Med J* 2000; 93(2): 511-3.